

# Rheumatic Heart Disease in Homozygous Familial Hypercholesterolemia - A Double Burden

Santhosh Krishnappa\*, Jayasheelan Mambally Rachaiah, Kanchanahalli Siddegowdasadananda, Manjunath Cholenahally Nanjappa

Department of Cardiology, Sri Jayadeva Institute of Cardiovascular Sciences and Research, Irwin Road, K R Hospital Premises, Mysore, Karnataka, INDIA.

## ABSTRACT

Homozygous familial hypercholesterolemia is a very rare disorder. Rheumatic heart disease is a common disease in developing countries. The simultaneous occurrence of these two conditions in the same patient is extremely rare. We describe a patient who had both these conditions and discuss the management issues.

**Key words:** Homozygous hypercholesterolemia, Supra valvular aortic stenosis, Rheumatic heart disease, Familial hypercholesterolemia.

## Correspondence

Santhosh Krishnappa

Department of Cardiology,

Sri Jayadeva Institute of Cardiovascular Sciences and Research, Irwin Road, K R Hospital Premises, Mysore, Karnataka, INDIA.

Ph.no: +91990063617

E-mail address: drsanthoshk@gmail.com

Submission Date: 29-12-2017;

Revision Date: 23-01-2018;

Accepted Date: 24-02-2018.

DOI : 10.5530/jcdr.2018.2.25

## INTRODUCTION

Familial hypercholesterolemia is a rare autosomal dominant disorder with diverse clinical presentation. It is characterized by high LDL-cholesterol levels, premature coronary artery disease (CAD), valvar or supra valvular aortic stenosis and cutaneous xanthomas.<sup>1-2</sup> Rheumatic heart disease is a common disorder in the developing world. We report an unusual case presenting with a combination of familial homozygous Hypercholesterolemia and rheumatic mitral regurgitation.

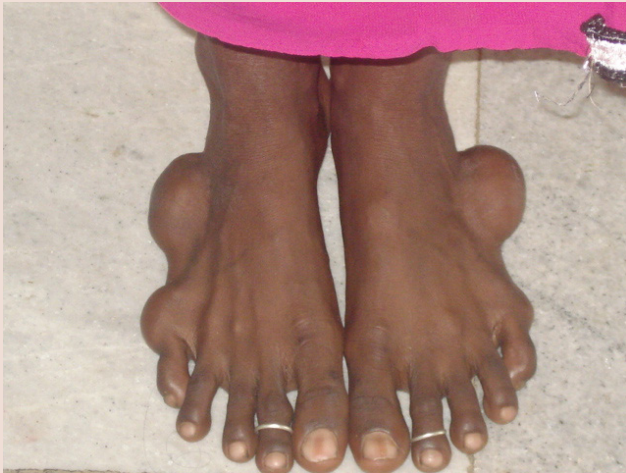## CASE PRESENTATION

A 28 year old woman was referred by her family physician for evaluation of cardiac murmur and symptoms of atypical chest pain. On evaluation, her vitals were normal. She had bilateral tendon xanthomas over the elbows, achillis tendon, lateral margin of the foot (Figure 1) and buttocks. A Grade III/VI ejection systolic murmur was heard in the first right intercostal space and a Grade III/VI pansystolic murmur was heard at the apex. The Electrocardiogram was normal. Her total cholesterol was 509 mg/dl, LDL-cholesterol was 403 mg/dl, VLDL-cholesterol was 63 mg/dl, HDL-cholesterol was 43.3 mg/dl and Triglycerides was 313 mg/dl. Transthoracic echocardiography revealed normal cardiac chamber dimensions and function without any regional wall motion abnormalities. The aortic valve was normal (Figure 2A). There was a discrete narrowing of the aorta, just above the Sino tubular junction with mild post stenotic dilatation (Figure 2A and 2B). The mean gradient across the stenosis was 29/15 mm of Hg. The AML and PML were thickened and the mobility of PML was markedly restricted (Figure 3A and 3B). The chordae and Papillary muscles were likewise thickened suggesting a rheumatic etiology (Figure 3A and 3B). There was moderate mitral valve regurgitation on colour doppler (Figure 3A). In view of the patient's symptomatology and the high possibility of coronary artery disease a coronary angiogram was performed. The coronary angiogram revealed ostial right coronary artery stenosis of 50%, ostial left main artery stenosis of 20%, and ostial left circumflex artery stenosis of 30%. An LV angiogram in LAO view clearly demonstrated the supra valvular aortic stenosis (Figure 4). A pull back gradient of 21 mm hg was observed across this stenosis. Hence a final diagnosis of familial hypercholesterolemia with premature coronary artery disease, supra valvular aortic stenosis and rheumatic mitral regurgitation was made. Interestingly, the patient's mother also had tendon


xanthomas and Hypercholesterolemia and had died of a myocardial infarction in her fifth decade. Her father had hypercholesterolemia with no other coronary risk factors, and he too had died of a myocardial infarction in his sixth decade. As her coronary lesions were not significant, the patient was advised a conservative management with aspirin, high-dose atorvastatin (40 mg/day), ezetimide, a low cholesterol diet and regular follow-up. She was also advised Benzthine penicillin prophylaxis for the RHD.

## DISCUSSION

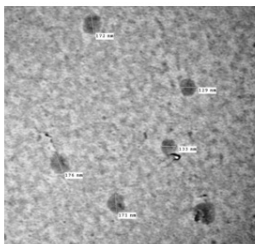
Familial hypercholesterolemia is an autosomal dominant disorder of defect in LDL receptor gene resulting in a reduction in the number or function of LDL receptors.<sup>3</sup> This leads to high LDL cholesterol levels, formation of xanthomas and increased tendency of atheroma in the vascular structure, preferentially in the coronaries<sup>4</sup> and ascending aorta.<sup>5</sup> Premature coronary artery disease predominantly involving the ostial/proximal portion of the coronaries is a well recognized entity in this condition.<sup>6-7</sup> Premature CAD develops in the first two decades in homozygotes and in the early to mid-adulthood in heterozygotes. Supra valvular aortic stenosis is a characteristic feature of homozygous familial hypercholesterolemia.<sup>5,8</sup> Despite the association, it still remains to be explained why raised serum cholesterol has a predilection for deposition in the aortic root in familial hypercholesterolemia.<sup>9</sup> One of the postulations put forth by summers *et al.*<sup>10</sup> is, that it is due to altered growth of the vessel wall, because the atherosclerosis of HFH occurs at such an early age. High LDL concentrations might repress the expression of genes related to aortic growth. Summers *et al.*<sup>10</sup> found that 41% of their patients had supra valvular aortic stenosis on MRI and 86% of these patients had plaques in the aorta as well. In addition, valvar aortic stenosis has also been described. Degenerative mitral valve involvement has been described by Buja *et al.* in 11 out of his 21 patients in homozygous familial hypercholesterolemia.<sup>11</sup> However, thickening of the chordae, papillary muscles and mitral leaflets; and PML restriction are specific to Rheumatic etiology and not seen in degenerative mitral valve disease. The prevalence of RHD in india is 1-5.4 per 1000 children<sup>12-13</sup> and the frequency of FHC is 1 in 1 million individuals in the homozygous form.<sup>14-15</sup> The present report of a combination of familial homozygous Hypercholesterolemia and rheumatic heart disease has not been reported earlier. Treatment



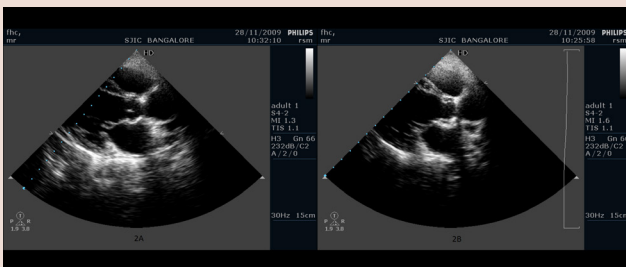
**Figure 1:** Tendon Xanthomas.



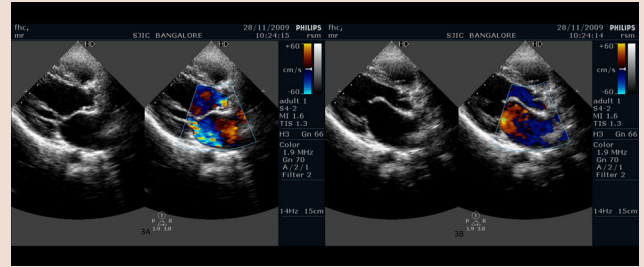
**Fig. 1** Scanning electron micrographs (SEM) of silymarin powder (A), nanocrystals (B) and phytosomes



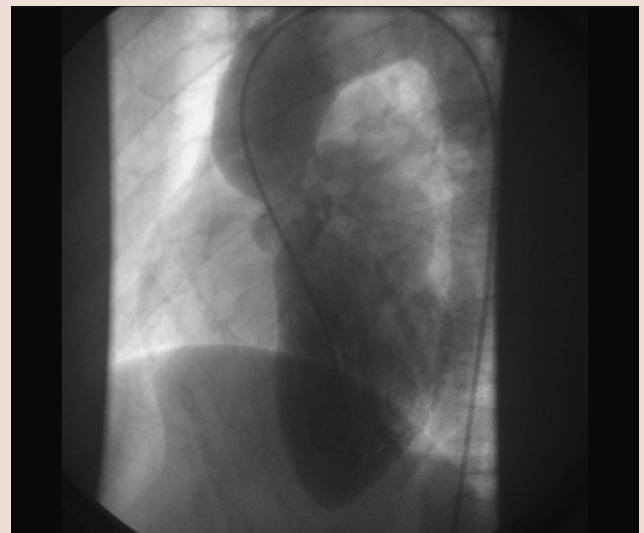
**Figure 1:** Tendon Xanthomas.



**Figure 2:** Discrete narrowing of the aorta, just above the sinotubular junction with mild post stenotic dilatation.



**Figure 3:** Thickening, restricted mobility of anterior, posterior mitral leaflet, chordae tendinae and papillary muscles suggesting a rheumatic etiology.



**Figure 4:** LV angiogram in LAO view demonstrating supralvalvular aortic stenosis.

of FHC is difficult. Weekly/biweekly plasmapheresis forms the cornerstone therapy of FHC.<sup>16</sup> However, it is expensive, time consuming and not available to many patients. Despite the deficiency of LDL receptors, high dose statins have been shown to lower LDL-C levels in FHC by upto 15 and 21% in patients with or without plasmapheresis/portocaval shunt respectively by increasing LDL catabolism. Ezetimibe, a cholesterol absorption inhibitor, further reduced LDL-C levels by 20.5% when added to maximal statin therapy. Liver transplantation, by providing functional LDL receptors, has been shown to normalize LDL values.<sup>17</sup> A majority of patients with FHC subsequently require percutaneous or surgical intervention for their premature coronary artery disease or aortic stenosis and/or supralvalvular aortic stenosis. The added dimension of RHD in our patient further aggravates the clinical complexity. No therapy has till date been shown to regress mitral regurgitation. As MR begets MR, the severity of MR will increase necessitating an intervention in due course. The double burden of FHC and RHD in our patient presents a uniquely challenging clinical scenario.

## CONFLICT OF INTEREST

The authors declare no conflict of interest.

## ABBREVIATIONS

**LDL:**Low-Density Lipoproteins, **HDL:** High-density lipoproteins, **VLDL:** Very Low-Density Lipoproteins. **CAD:** Coronary Artery Disease; **AML:** Anterior mitral leaflet; **PML:** posterior mitral leaflet; **LV:** Left ventricle; **LAO:** left anterior oblique; **HFH:** Homozygous familial hypercholesterolemia; **MRI:** Magnetic resonance imaging; **FHC:** Familial hypercholesterolemia; **RHD:** Rheumatic heart disease; **MR:** Mitral regurgitation.

## SUMMARY

Familial hypercholesterolemia is a rare autosomal dominant disorder, can have a diverse clinical presentation and stormy course. Rheumatic heart disease in this patient is an added burden. A majority of this patients require medical or surgical interventions, but none of them are curable. The complexity and diversity of this two conditions make it more unique and challenging to treat.

## REFERENCES

1. Shankarappa RK, Moorthy N, Bhat SP, Dwarakaprasad R, Nanjappa MC. Cardiology in the young. 2009;19(3):257-63.
2. Ozumi K, Tasaki H, Yamashita K, Tanaka S, Sasaguri T, Sasaguri Y, *et al.* Valvular and supra-ventricular aortic stenosis in heterozygous familial hypercholesterolemia, a case report. *Atheroscler Thromb.* 2005;12(5):289-93.
3. Tarui S. Classification and diagnosis criteria of primary hyperlipidemia, Ministry of Welfare, Study Report.1988:26-34.
4. Marks D, Thorogood M, Neil HA, Humphries SE. A review on the diagnosis, natural history, and treatment of familial hypercholesterolemia. *Atherosclerosis.*

- 2003;168(1):1-14.
5. Brook GJ, Keider S, Boulos M, Grenadier E, Wiener A, Shehada N, *et al.* Familial homozygous hypercholesterolemia: Clinical and cardiovascular features in 18 patients. *Clin Cardiol.* 1989;12(6):333-8.
6. Sprecher DL, Schaeffer EJ, Kent KM, Gregg RE, Zech LA, Hoeg JM, *et al.* Cardiovascular features of homozygous familial hypercholesterolemia: Analysis of 16 patients. *Am J Cardiol.* 1984;54(1):20-30.
7. Allen JM, Thompson GR, Myant NB, Steiner R, Oakly CM: Cardiovascular complications of homozygous familial hypercholesterolemia. *Br Heart J.* 1980; 44(4):361-8.
8. Wennenvold A, Javobsen JG: Acquired supra-ventricular aortic stenosis in familial hypercholesterolemia. A hemodynamic and angiographic study. *Am J Med.* 1971;50(6):823-7.
9. Kawaguchi A, Yutani C, Yamamoto A. Hypercholesterolemic valvulopathy: An aspect of Malignant Atherosclerosis. *Therapher Dial.* 2003;7(4):439-43.
10. Summers RM, Andrasko-Bourgeois J, Fuerenstien IM, Hill SC, Jones FC, Busse MK, *et al.* Evaluation of the aortic root by MRI: Insights from the patients with homozygous familial hypercholesterolemia. *Circulation.* 1998;98(6):509-18.
11. Buja LM, Kovanen PT, Bilheimer DW. Cellular pathology of homozygous familial hypercholesterolemia. *Am J Pathol.* 1987;97(2):327-58.
12. Grover A, Vijayvergiya R, Thingam ST. Burden of rheumatic and congenital heart disease in India: lowest estimate based on the 2001 census. *Indian Heart J.* 2002;54:104-7.
13. Jose JV, Gomathi M. Rheumatic Heart Disease: Declining Prevalence of Rheumatic Heart Disease in Rural Schoolchildren in India: 2001-2002 *Indian Heart J.* 2003;55(2):158-60.
14. Rallidis L, Naoumova RP, Thompson GR, Nihoyannopoulos P. Extent and severity of atherosclerotic involvement of the aortic valve and root in familial hypercholesterolemia. *Heart.* 1998;80(6):583-90.
15. Goldstein JL, Brown MS: The LDL receptor defect in familial hypercholesterolemia. Implications for pathogenesis and therapy. *The Medical Clinics of North America*, ed by Havel RJ, WB Saunders, Philadelphia. 1982;66(2):335-62.
16. Zwiener RJ, Uauy R, Petruska ML, Huet BA. Low-density lipoprotein apheresis as long-term treatment for children with homozygous familial hypercholesterolemia. *J Pediatr.* 1995;126(5):728-35.
17. Hoeg JM. Pharmacologic and surgical treatment of dyslipidemic children and adolescents. *Ann NY AcadSci.* 1991;623(1):275-84.

**Cite this article :** Krishnappa S, Rachaiah JM, Siddegowdasadananda K, Nanjappa MC. Rheumatic Heart Disease in Homozygous Familial Hypercholesterolemia - A Double Burden. *J Cardiovasc Disease Res.* 2018; 9(2):106-8.