

# Saccular Aneurysm of Aortic Arch at Inferior Surface

Parth Solanki\*, Jignesh Kothari, Devvrat Desai, Kinnarsh Baria

Department of Cardiovascular and Thoracic Surgery, U.N. Mehta Institute of Cardiology and Research Center, (Affiliated to B.J. Medical College), Civil hospital Campus, Asarwa, Ahmedabad, Gujarat, INDIA.

## ABSTRACT

Aortic arch saccular aneurysm is a very rare presentation. Due to the imminent danger of rupture, most of the vascular surgeons prefer to repair as and when diagnosed. Here we are presenting a case of the unruptured saccular aneurysm and our experience. We are discussing a rare presentation of hemoptysis in the patient of saccular distal arch aneurysm.

**Key words:** Aortic arch, Saccular aneurysm, Aortic aneurysm.

## Correspondence

Dr. Parth Solanki

Assistant Professor, Department of Cardiovascular and Thoracic Surgery, U. N. Mehta Institute of Cardiology and Research Center, (Affiliated to B. J. Medical College), New Civil Hospital Campus, Asarwa, Ahmedabad-380016, Gujarat, INDIA.

Ph.no: +91 9825798542

E-mail address: parthdoc@yahoo.co.in

Submission Date: 28-08-2018;

Revision Date: 07-09-2018;

Accepted Date: 17-02-2019.

DOI : 10.5530/jcdr.2019.1.9

## INTRODUCTION

Aneurysm is a permanent dilation characterized by 50% greater diameter than the normal vessel.<sup>1</sup> There are two types of aortic aneurysm 1) fusiform and 2) saccular. In True aneurysm all three layers of the vessel wall are intact; false aneurysm, in which none of the three layers are intact; or pseudoaneurysm, in which one or two layers remains intact.<sup>2-3</sup> Usually, true aneurysms are fusiform and false aneurysms are saccular,<sup>2</sup> but this is not a general rule.

We present here a case of large saccular arch aneurysm who presented with complain of one episode of hemoptysis and left sided chest pain.

## CASE HISTORY

Male patient of age 61 year presented in our OPD with chief complain of left chest pain atypical in nature and one episode of massive hemoptysis. It was treated at peripheral hospital conservatively and patient was referred to us for further management. ECG of the patient was normal. In echocardiography we came to know that there was a saccular aneurysm in the distal aortic arch. To confirm a diagnosis we performed contrast enhanced computer tomography of the ascending aorta and arch and descending aorta. The finding of the CT scan was a large saccular aneurysm in distal aortic arch with circumferential mural thrombus arising from left lateral aspect of arch projecting to left pleural space. The aneurysm was firmly adherent to left upper lobe with erosion of the part of upper lobe which was the cause of hemoptysis.

Aneurysm measures 59.8 x 46.3 x 38.3 mm total,  
38 x 26 x 16 mm PATENT PART.

Ascending descending and abdominal aorta were normal. (Figure 1)

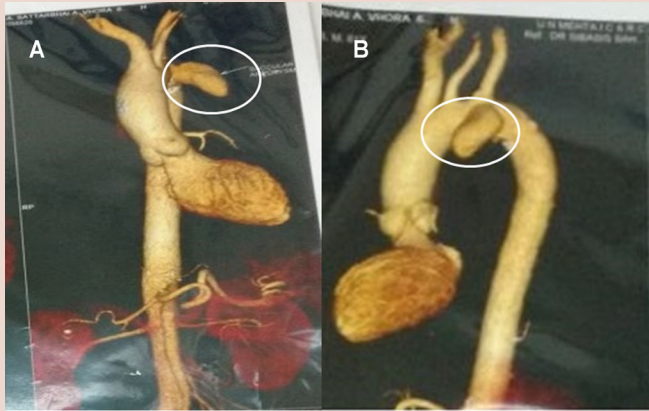
## Operative strategy

Operation was performed with midline sternotomy. After doing sternotomy and opening the pericardium we encountered severe adhesions between pulmonary artery and left lung involving aneurysm. After adhesiolysis, the aneurysm was found at the under surface of distal aortic arch. (Figure 2 A) We used different cannulation strategy. (Figure 3 A, B) Arterial cannulation was done in right innominate artery and right femoral artery. Left common carotid artery was isolated and snared. We used this strategy for brain protection as well as maintaining the lower body perfusion. We could apply clamp without compromising perfusion and isolate operative field. Clamp was applied just proxi-

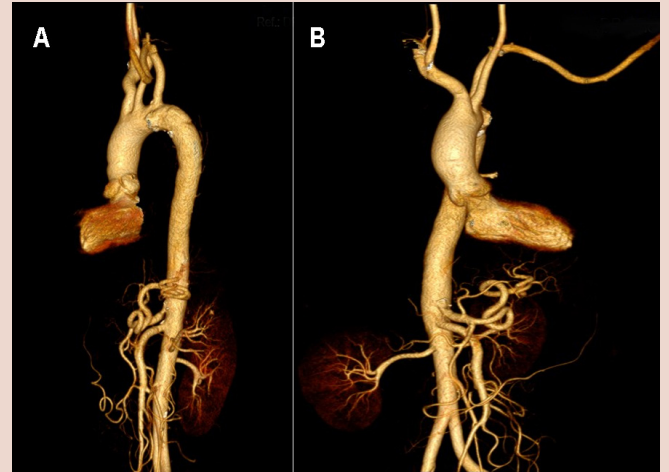
mal to aneurysm and patient was cooled to 20 with low flow perfusion. A sum sucker was kept in aneurysm while repairing. Venous cannulation was done by two stage cannula in right atrium. We identified the aneurysm and clamped the distal arch proximal and distal to the aneurysm and cut open the aneurysm, (Figure 2 B, C) put a 30 mm by 30 mm polytetrafluoroethylene (PTFE) patch over it and closed the defect in aorta. (Figure 2 D) Patient was wean from CPB. The part of the left upper lobe involved in adhesions with aneurysm was sutured enmass to conceal the defect formed by the aneurysmal adhesions. Post-operative course was uneventful. Patient was discharged from the hospital on 10<sup>th</sup> postoperative day. A repeat CT aortogram was performed on the day of discharge. In post-operative CT aortogram we confirmed complete repair of the aneurysm. (Figure 4 A, B) Patient came on follow-up with no complains after 6 months.

## DISCUSSION

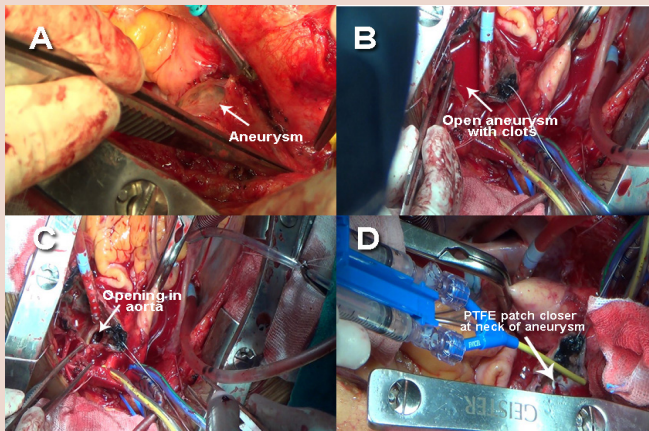
In our case the only possible reason we found was atherosclerosis. The diagnosis of true and false aneurysm becomes difficult in saccular type if filled with thrombus. In our case the aneurysm was true as all the layers were involved. Other causes of aneurysm are syphilis, connective tissue disorder like ehler danlos syndrome, marfans syndrome. The only treatment of saccular aneurysm is definitive surgery or endovascular repair. Endovascular repair was difficult to conspicuous position of aneurysm and great vessels. Different surgical techniques are used in saccular aneurysms,<sup>4</sup> in such limited aneurysm we preferred resection of the aneurysmal sac and repair the aorta with PTFE patch. The only diagnostic tool in saccular aneurysms is computerized tomography. As the age of the patient increases the atherosclerotic process also progresses<sup>5</sup> and the aneurysm enlarges more in case of uncontrolled hypertension. Postoperatively it is very important to control hypertension in such patients. In surgical closure of the defect after resecting aneurysm the surrounding adherent fibrous tissue should be included in sutures for additional strength of sutures. It is very important to include all the layers of aorta in sutures, to prevent development of false aneurysm along the edges of the suture line. The presentation was unusual and rare, in our case the site of the aneurysm was very abnormal, it was exactly opposite the origin of subclavian artery and under surface of arch was real surgical challenge.



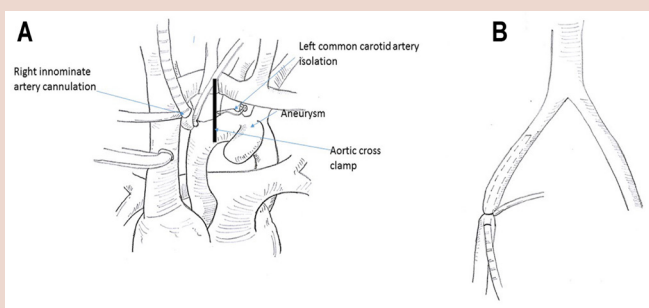
**Figure 1 (A, B):** image of saccular aneurysm found on the undersurface of distal aortic arch.



**Figure 4(A, B):** Complete repair of aneurysm by goretx patch seen in post-operative CT aortogram.



**Figure 2 (A):** Intraoperative figure of mouth of aneurysm found on the under surface of distal aortic arch. (B, C): After opening the aneurysm the mouth of the defect is seen. (D): Defect repaired by goretx patch is seen.



**Figure 3 (A, B):** Cannulation strategy.

## CONCLUSION

Surgical repair is the preferred treatment of saccular aortic aneurysm where facilities of endovascular stenting is not available and feasible. CT aortogram is the gold standard investigation to diagnose saccular aortic aneurysm. The repair of the aneurysm in distal aortic arch presents as a great surgical challenge due to its location and adhesion if present to the surrounding tissues.

## ACKNOWLEDGEMENT

I want to acknowledge Himani Pandya for assistance.

## CONFLICT OF INTEREST

The authors declare that there is no conflict of interest.

## ABBREVIATIONS

PTFE: Polytetrafluoroethylene patch, CPB: Cardio Pulmonary Bypass.

## REFERENCES

1. Johnston KW, Rutherford RB, Tilson MD, Shah DM, Hollier L, Stanley JC. Suggested standards for reporting on arterial aneurysms Subcommittee on Reporting Standards for Arterial Aneurysms, Ad Hoc Committee on Reporting Standards, Society for Vascular Surgery and North American Chapter, International Society for Cardiovascular Surgery. *J Vasc Surg.* 1991;13(3):452-8.
2. Kadir S. *Diagnostic angiography.* Philadelphia: Saunders. 1986;124-72.
3. Johnsrude IS, Jackson DC, Dunnick NR. *Practical approach to angiography.* 2<sup>nd</sup> ed. Boston: Little, Brown. 1987;532-40.
4. Taylor BV, Kalman PG. Sacculary aortic aneurysms. *Ann Vasc Surg.* 1999;13(6):555-9.
5. Dinsmore RE, Liberthson RR, Wismer GL, Miller SW, Liu P, Thompson R, et al. Magnetic resonance imaging of thoracic aortic aneurysms, comparison with other imaging methods. *AJR.* 1986;146(2):309-14.

**Cite this article :** Solanki P, Kothari J, Desai D, Baria K. Sacculary Aneurysm of Aortic Arch at Inferior Surface. *J Cardiovasc Disease Res.* 2019;10(1):50-1.