

# Lipomatous Hypertrophy of the Interatrial Septum Accompanied By Interatrial Septal Lipoma

Erdal Gursul<sup>1\*</sup>, Serdar Bayata<sup>2</sup>

<sup>1</sup>Biga State Hospital, Department of Cardiology, Canakkale, Turkey

<sup>2</sup>Katip Celebi University Atatürk Training and Research Hospital, Department of Cardiology, Izmir, Turkey

## ABSTRACT

Lipomatous hypertrophy of the interatrial septum (LHIS) is usually an incidentally detected benign disorder which is asymptomatic in most of the cases. On the other hand, cardiac lipomas are rare benign cardiac tumors. In transthoracic echocardiography (TTE) of a 77-year-old male patient, who was admitted with the complaint of dyspnea, homogeneous hypertrophic interatrial septum (IAS) was observed. Transesophageal echocardiography (TOE) detected a mass lesion on IAS in addition to LHIS. In cardiac magnetic resonance imaging (MRI), LHIS and an 18\*16 mm diameter mass in line with lipoma was observed in interatrial septum. Cardiac lipomas and LHIS are often benign formations yet they may require surgery in circumstances such as being symptomatic and/or large in diameter. Cardiac MRI, TTE, and TOE images of a patient with LHIS and interatrial septal lipoma extending into right atrial cavity are presented in this paper.

**Key words:** Cardiac lipomas, Cardiac MRI, Echocardiography, Lipomatous hypertrophy of the interatrial septum.

## INTRODUCTION

Lipomatous hypertrophy of the interatrial septum (LHIS) is an incidentally detected benign septal thickening and usually asymptomatic. Incidences of LHIS were 1% in autopsy series, 8% in transthoracic echocardiography (TTE), 2.2% in computer tomography (CT) and 2% in cardiac magnetic resonance imaging (MRI) studies.<sup>1-3</sup> These masses which can cause difficulty in breathing due to valve stenosis or venous occlusion and may also rarely induce atrial arrhythmia. Cardiac lipomas are rare cardiac benign tumors. The incidence of cardiac lipoma is between 0.001 % and 0.03 % in autopsy series.<sup>4</sup> Lipomas can be seen in all chambers of the heart. They are encapsulated most of the time and may extend into the cardiac chamber.<sup>4</sup> In this report TTE, TOE and cardiac MRI images of lipoma extending right atrium on LHIS surface of the patient who was referred our clinic with the complaint of dyspnea are presented.

## CASE REPORT

A 77 year old male patient was consulted with the complaint of recently increased dyspnea. His medical history revealed chronic bronchitis and arterial hypertension. In examination, body mass index was 22 m<sup>2</sup> / kg, blood pressure was 120/70 mmHg and pulse rate was 90/beats per minute. No pathological findings were observed in systemic examination except the pulmonary rhonchus in auscultation. Routine hemogram and biochemical parameters were within normal limits. The electrocardiogram showed normal sinus rhythm and p mitrale. Chest X-ray revealed normal cardiac silhouette. Transthoracic echocardiography (TTE) demonstrated homogeneous, hypertrophic interatrial septum with a maximum diameter of 18 mm at midpoint at (Figure 1-A, apical four chamber view). It was observed that the entire IAS was thicker in subcostal view and it became thinner in fossa ovalis region. No valve pathology was observed and left ventricular ejection fraction was estimated as 54%. Patient underwent transesophageal echocardiography (TOE) with the diagnosis of lipomatous hypertrophy of the interatrial septum. In TOE, a hyperechogenic thickening moving off from fossa ovalis region was detected with a diameter of 20\*15 mm at superior vena cava side and with a diameter of 20\*13 mm at inferior vena cava side which was observed more clearly on bicaval view (Figure

### \*Corresponding address:

Dr. Erdal Gursul, MD

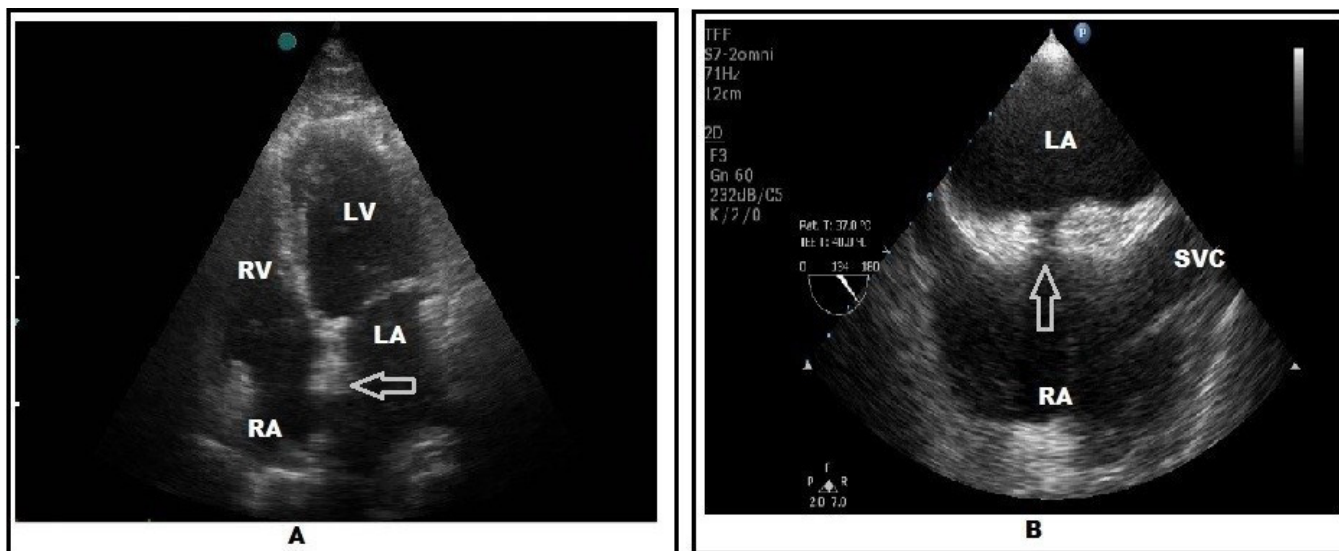
Department of Cardiology,

Biga State Hospital, Ozmen Street No: 124, Canakkale/Turkey.

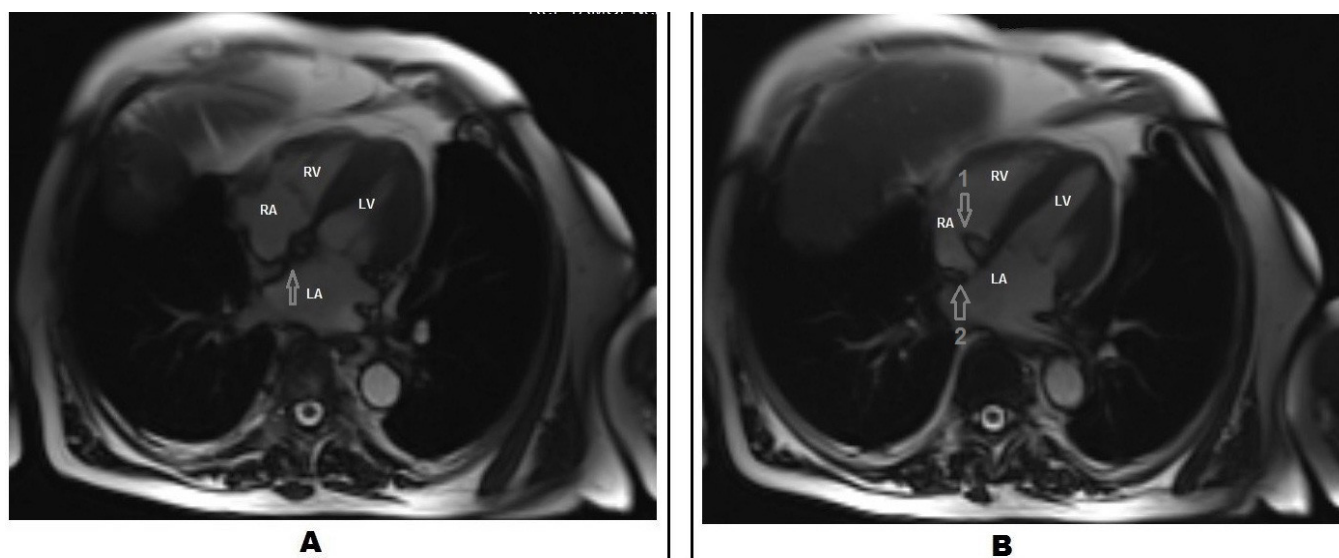
Phone no : +90 232 444 35 08 Fax no : 90 232 452 77 88

E-mail: erdalgrsul@yahoo.com.tr

DOI: 10.5530/jcdr.2015.1.9



**Figure 1(A):** The patient's transthoracic echocardiographic (TTE) image at four chamber view, arrow indicates lipomatous hypertrophy of the interatrial septum (LHIS). **(B):** The patient's transoesophageal echocardiography (TEE) image at bicaval view, arrow indicates characteristic 'dumbbell shape' of LHIS. RA: right atrium; LA: left atrium; LV: left ventricle; RV: right ventricle, SVC: superior vena cava.



**Figure 2(A):** The patient's cardiac magnetic resonance image (MRI) which indicates lipomatous hypertrophy of the interatrial septum (LHIS). **(B):** Arrow 1 indicates lipoma which arising from interatrial septum, arrow 2 indicates LHIS. RA: right atrium; LA: left atrium; LV: left ventricle; RV: right ventricle.

1-B). A more echogenic and nodular mass lesion than the current thickening was also detected. This mass lesion was extending into right atrium and had a diameter of 20\*14 mm. No ASD or PFO were observed. TEE examination was stopped earlier due to breathing difficulties while searching an angle for an image that involve both LHIS and the mass in the same frame. A cardiac MRI was planned for differential diagnosis of IAS hypertrophy and the extruding mass lesion. Paraxial and paracoronal sections were taken for morphological evaluation while sections with four and two cavities were obtained for functional evaluation by using 7.5 ml contrast agent. On cardiac MRI,

an adipose deposition (interatrial lipomatous hypertrophy) extending into basement was spotted on IAS (Figure 2-A). A non-contrast enhancement, 18\*16 mm diameter, nodular encapsulated mass lesion (lipoma) which displayed septal localization and adipose tissue continuity, and generated signal loss in adipose-suppressed sequences was monitored as facing right atrium cavity (Figure 2-B). Surgical intervention was not considered for the patient because of absence of complications such as valve occlusion and hemodynamic compromise. Close observation of patient with regular TTE applications were planned. Dyspnea complaint of the patient was linked to his existing chronic

bronchial disease. An informed consent from was taken from the patient by giving information about disease and scientific contribution.

## DISCUSSION

Lipomatous hypertrophy of the interatrial septum is described as thickening of IAS with adipose tissue (>2 cm) while its etiology has not been properly enlightened.<sup>5</sup> According to some authors, formation mechanism of LHIS is resulted from transformation of primitive atrium generating embryonic mesenchymal cells present on IAS to adipose tissue by a stimulator.<sup>6,7</sup> While actual incidence cannot be determined clearly due to being asymptomatic, it was found as 1% in autopsy series.<sup>1</sup> It is reported that LHIS generally occurs in elderly and obese patients and in some publications it is shown to have dominancy in women.<sup>1,8-10</sup> While LHIS usually exists asymptotically, it causes difficulty in breathing when it suppresses tricuspid valve or venous structures by reaching massive diameters. It is supported by studies that LHIS can induce arrhythmia and LHIS related p wave alterations, atrial arrhythmias and sudden cardiac deaths.<sup>8,10-13</sup> The characteristic appearance of top and/or bottom part of interatrial septum which seems to be separated from foramen ovale is called as 'dumbbell shape'. The LHIS presented in our study displays this characteristic appearance. TEE is one of the first investigations to be applied for a LHIS diagnosis. CT and MRI are further tests to display adipose accumulation or hypertrophy. It is exhibited with MRI screening that interatrial adipose accumulation and subcutaneous adipose tissue have the same density.<sup>14,15</sup>

Seventy percent of the heart tumors are non-malignant and most of them form myxomas. Lipomas are rarely encountered non-malignant cardiac tumors. Cardiac lipoma incidence is between 0.001 % and 0.03 % in autopsy series.<sup>4</sup> They are more often asymptomatic and they can be seen in all four chambers of the heart. Lipomas are most frequently encountered in left ventricle. They can originate from parietal or visceral pericardium.<sup>4,5</sup> MRI occupies an important place in diagnosis of lipomas which have homogeneous, well-circumscribed mass appearance. Lipomas can be symptomatic by causing stenosis in valve and venous structures particularly when they reach to massive diameters. In such cases, they should be removed by surgical operations and their post operative prognoses are excellent.<sup>5</sup>

While LHIS is more frequently encountered in elderly,

obese people and women; lipomas equally impact males and females and in all ages.<sup>1,5,8-11</sup> Thickening in LHIS occurs along the atrial septum without encapsulation whereas lipomas are encapsulated tumors which generally extend into cavities and can be seen in other regions of the heart.<sup>1,4,5</sup> LHIS differs from lipomas by displaying ample multi-vacuolated lipocytes and hypertrophic myocytes in their histopathologic examinations.<sup>9</sup>

In our case, asymptomatic LHIS and interatrial septal lipoma are presented together on interatrial septum. No publications regarding encapsulated lipoma extending into right atrium on lipomatous hypertrophy of the interatrial septum surface were encountered in literature research. Because of absence of obstruction findings, we did not surgery considered surgery and echocardiographic follow-up was scheduled.

## CONCLUSION

A case that had asymptomatic LHIS and interatrial septal lipoma in the same area was presented. No publications regarding encapsulated lipoma extending into right atrium on lipomatous hypertrophy of the interatrial septum surface were encountered in literature. Cardiac lipomas and LHIS are often benign formations yet they may require surgery in circumstances such as being symptomatic and/or large in diameter.

## CONFLICT OF INTEREST

Authors declared no conflict of interest

## ACKNOWLEDGEMENTS

We would like to thank Birsal Sen Akova for evaluating the cardiac magnetic resonance images.

## LIMITATIONS OF THE STUDY

Macroscopic and microscopic (histopathological) examination and imaging of hypertrophy and the mass cannot be performed because of absence of surgical indication. TEE examination was stopped earlier due to breathing difficulties while searching an angle for an image that involve both LHIS and the mass in the same frame. Therefore, a TEE image which involves lesions together could not be reached.

## REFERENCES

1. Reyes CV, Jablolkow VR. Lipomatous hypertrophy of the cardiac interatrial septum: a report of 38 cases and review of the literature. *Am J Clin Pathol.* 1979; 72(5): 785-8.
2. Pochis WT, Saeian K, Sagar KB. Usefulness of transesophageal echocardiography in diagnosing lipomatous hypertrophy of the atrial septum with comparison to transthoracic echocardiography. *Am J Cardiol.* 1992; 70(3): 396-8.
3. Heyer CM, Kagel T, Lemburg SP, Bauer TT, Nicolas V. Lipomatous Hypertrophy of the Interatrial Septum: A Prospective Study of Incidence, Imaging Findings, and Clinical Symptoms. *CHEST Journal* 2003; 124(6): 2068-73.
4. Sabatine MS, Colucci WS, Schoen FJ. Primary tumors of the heart. In: Zipes DP, Libby P, Bonow RO, Braunwald E. *Braunwald's Heart Disease.* 7<sup>th</sup> ed. Philadelphia: Elsevier Saunders; 2005. p. 1741-55.
5. Burke A, Virmani R. Tumors of the heart and great vessels. *Atlas of Tumor Pathology.* 3<sup>rd</sup> ed. Washington: Armed Forces Institute of Pathology; 1996. p. 1-98.
6. Meaney JFM, Kazerooni EA, Jamadar DA, Korobkin M. CT appearance of lipomatous hypertrophy of the interatrial septum. *AJR Am J Roentgenol.* 1997; 168(4): 1081-4.
7. Rahilly R, Muller F. *The cardiovascular and lymphatic systems. Human embryology and teratology.* 2<sup>nd</sup> ed. New York: Wiley; 1992. p. 107-35.
8. Shirani J, Roberts WC. Clinical, electrocardiographic and morphologic features of massive fatty deposits ("lipomatous hypertrophy") in the atrial septum. *J Am Coll Cardiol.* 1993; 22(1): 226-38.
9. Burke AP, Litovsky S, Virmani R. Lipomatous hypertrophy of the atrial septum presenting as a right atrial mass. *Am J Surg Pathol.* 1996; 20(6): 678-85.
10. Gay JD, Guileyardo JM, Townsend-Parchman JK, Ross K. Clinical and morphologic features of lipomatous hypertrophy ("massive fatty deposits") of the interatrial septum. *Am J Forensic Med Pathol.* 1996; 11(1): 43-8.
11. Köhler U, Bittinger A. Lipomatöse hypertrophie des vorhofseptums: kardial bedingte synkope bei hamartom des rechten vorhofs. *Dtsch Med Wochenschr.* 1991; 116(1): 1393-6.
12. Colucci WS, Schoen FJ, Braunwald E. Primary tumors of the heart. In: Braunwald E, ed. *Heart disease.* 5<sup>th</sup> ed. Philadelphia: WB Saunders; 1997. p. 1464-77.
13. Hutter AM, Page DL. Atrial arrhythmias and lipomatous hypertrophy of the cardiac interatrial septum. *Am Heart J.* 1971; 82(1): 16-21.
14. Kaplan KR, Rifkin MD. Diagnosis of lipomatous infiltration of the interatrial septum. *AJR.* 1989; 153(3): 495-6.
15. Salantri JC, Pereles FS. Cardiac lipoma and lipomatous hypertrophy of the interatrial septum: cardiac magnetic resonance imaging findings. *Journal of computer assisted tomography* 2004; 28(6): 852-6.