

## A case of arrhythmogenic right ventricular cardiomyopathy in a middle-aged woman

He Jiang, Tao Zhang, Lihua Shang, Jian Cui, Jingzhe Liu, Yan Weng, Lin Gu, Yanhui Li, Qingyu Wu

*Heart Center, First Hospital of Tsinghua University, Beijing, People's Republic of China*

**Address for correspondence:** Dr. Yanhui Li, Heart Center, First Hospital of Tsinghua University, No. 6, 1<sup>st</sup> Avenue, Jiuxianqiao Road, Chaoyang District, 100 016 Beijing, People's Republic of China.  
E-mail: Yanhui.Li@Jcdronline.org

### ABSTRACT

Arrhythmogenic right ventricular cardiomyopathy (ARVC) is a kind of heart muscle disease characterized by the gradual replacement of the right ventricular myocardium with fibrous tissue and fat. It could be the major cause of sudden cardiac death with ventricular tachycardia, and there is a variation in the history of the disease. We reported an unusual case of ARVC in a middle-aged woman with congestive heart failure as her first presentation for a long time.

**Key words:** Arrhythmia, cardiomyopathy, right ventricle, heart failure

### INTRODUCTION

Since the first description was more than 20 years ago,<sup>[1]</sup> arrhythmogenic right ventricular cardiomyopathy (ARVC) is increasingly recognized from pathology to diagnosis. The main pathologic feature is the gradual replacement of the right ventricular myocardium by fibrous tissue and fat. It mainly leads to the structural and functional abnormalities of the right ventricle. However, sometimes the left ventricle is also involved. The clinical presentations of ARVC patients are variable.<sup>[2]</sup> Patients with ARVC often die at a young age due to the fatal ventricular arrhythmias whereas ARVC of an elder person is rare and different from that of young people. In this report, an unusual case of ARVC with a long, natural history in a middle-aged woman is presented.

### CASE REPORT

A 54-year-old woman was presented with progressive weakness, severe edema, and moderate shortness of breath on exertion for 9 years. It was considered to be congestive heart failure. In the last 2 years, syncope or presyncope associated with palpitations appeared. Subsequently, she was found to have monomorphic ventricular tachycardia (VT) with left bundle branch block-type morphology. Rest electrocardiogram displayed atrial fibrillation rhythm, epsilon wave, and negative T-waves in leads V1 to V4 [Figure 1]. It could be found from the echocardiography that there was severe dilation of the right ventricle, with a poor right ventricular (RV) systolic function and severe tricuspid valve regurgitation and decreased left ventricular ejection fraction [Figure 2]. An electrophysiological study showed VT of a right ventricular outflow tract or RV apex origin. As a diagnosis of ARVC was most likely, the patient underwent a magnetic resonance imaging scan which revealed diffuse areas of fat tissue at the right ventricular wall especially at the free wall [Figure 3]. At the same time, multiple small aneurysms were also found. The left ventricular free wall and interventricular septum were intact. Based on the clinical presentation and work-up, a definite diagnosis of ARVC was made. She refused implantable

#### Access this article online

Quick Response Code:

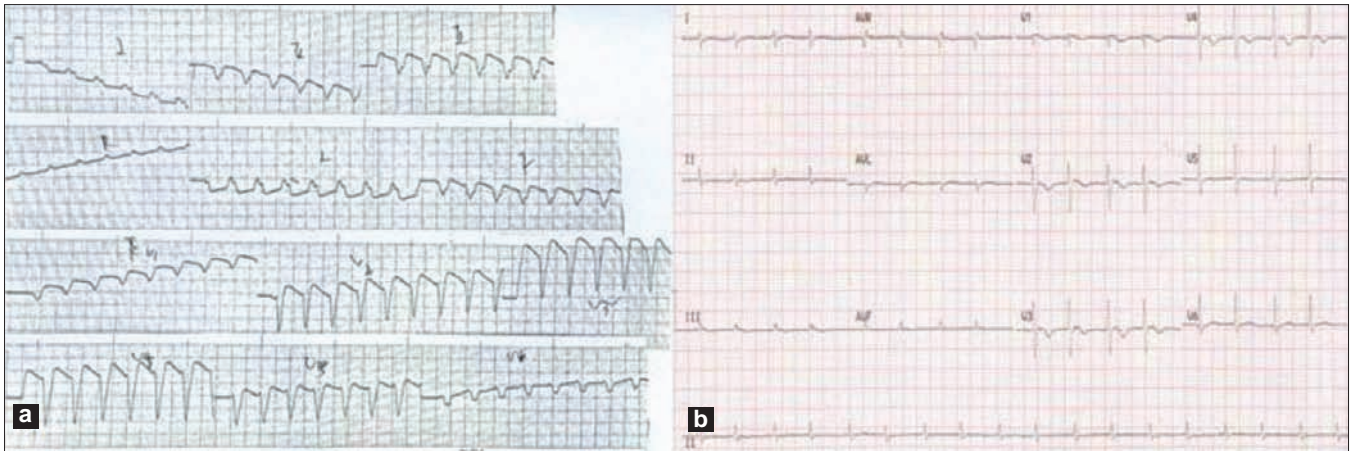


Website:

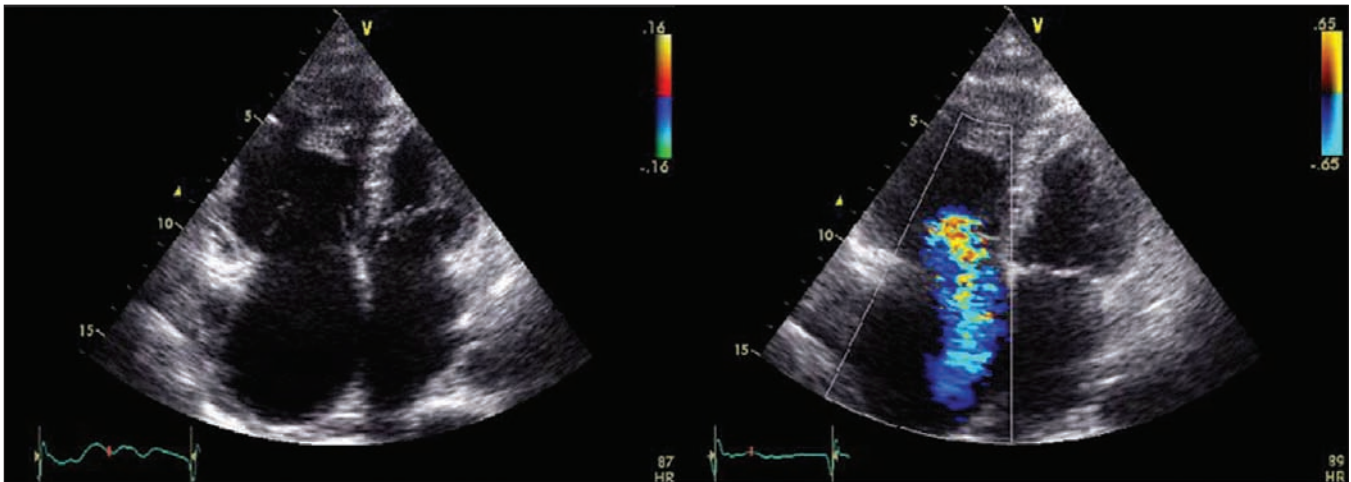
[www.jcdronline.com](http://www.jcdronline.com)

DOI:

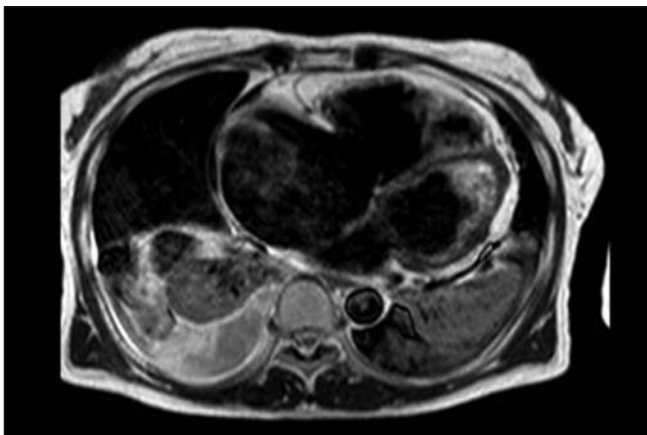
10.4103/0975-3583.78602



**Figure 1:** (a) 12-lead ECG recording of VT with left bundle branch block morphology. (b) 12-lead ECG with inverted T-waves and postexcitation epsilon wave in leads V1 to V4



**Figure 2:** Echocardiography image in the parasternal long axis showing severe dilation of the right ventricle and severe tricuspid valve regurgitation



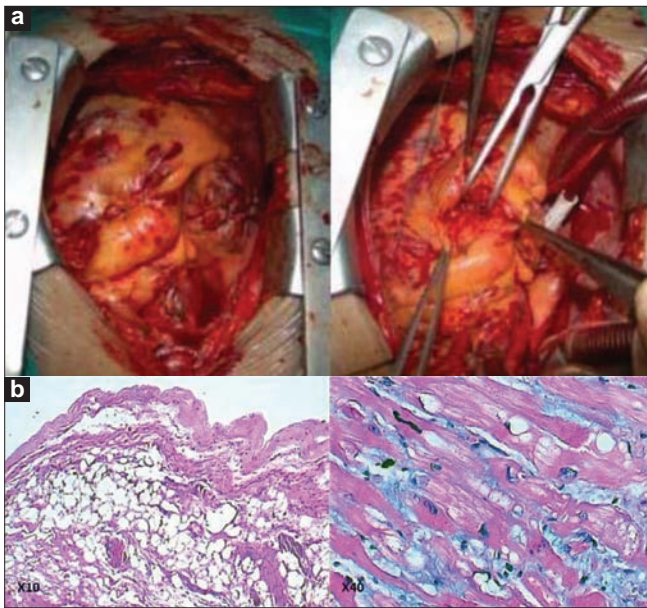
**Figure 3:** MRI showing the dilation of RV and transmural fibrofatty replacement in the RV free wall

cardioverter defibrillator (ICD) implantation and heart transplantation. She was treated with various antiarrhythmic

agents and angiotensin-converting enzyme inhibitors (ACEIs), diuretics, and  $\beta$ -blockers. Despite aggressive medical therapy, her clinical conditions continued to deteriorate, and the tricuspid valve repair was performed because of severe tricuspid valve regurgitation. She died of a lower cardiac output on the third day after the surgery. The general and cardiac biopsy findings demonstrated diagnosis was consistent with ARVC [Figure 4].

## DISCUSSION

ARVC is a heart muscle disease which is characterized by prominent, severe ventricular arrhythmias. The diagnosis of ARVC was once based on the Task Force criteria. However, the criteria have been found to be poorly sensitive and specific, especially in the early stage of the disease. So the criteria were revised in 2010.<sup>[3]</sup> The new



**Figure 4:** (a) A gross photograph demonstrating the right ventricular with extensive fatty replacement primarily involving the lateral wall. (b) Typical histologic features of ARVC, ongoing myocyte death with early fibrosis and adipocyte infiltration

criteria continues with these same categories: global or regional dysfunction and structural alternations; tissue characterization of the wall; repolarization abnormalities; depolarization abnormalities; and arrhythmia and family history. The categorization provides more measurable criteria removing some of the interpretation in the old criteria. This made the new criteria more sensitive and specific than the original one.

ARVC is an important cause of sudden cardiac death in people less than 65 years of age.<sup>[4]</sup> The symptoms are variable from person to person. They include chest discomfort, palpitations, presyncope, syncope, and unexplained heart failure. Although the right ventricle is mainly involved in ARVC, the left ventricle may be progressively affected thus resulting in biventricular failure. Progressive heart failure is more obvious in elder patients.<sup>[5]</sup> The heart muscles of the patient in our case were replaced by fibrous tissue and fat. This is an important reason for heart failure. And this heart failure may lead to hemodynamic or arrhythmic death.

The electrophysiological study carried out on the patient showed that there were a lot of low-voltage districts in the heart. And this caused the failure of radiofrequency catheter ablation (RFCA) on VT. So the treatment of ARVC is yet focused on ICDs for the prevention of sudden cardiac death. The patients with malignant ventricular arrhythmia may benefit greatly from ICD implantation. Heart transplantation is unusual in ARVC but it has been performed at the end stage of heart failure.<sup>[6]</sup> Because of cardiac myocyte loss (fat and fibrous tissue replacement) in the right ventricle, the patient would benefit when she accepted an operation of heart transplantation, not the tricuspid valve repair for her severe heart failure.

## CONCLUSIONS

The patient did not present with the common symptoms of ARVC. Heart failure may be more obvious in elder patients. Although ARVC is an inherited disease of the heart muscles involving the right ventricle, the left ventricle may be progressively affected thus resulting in a biventricular failure. This heart failure may lead to hemodynamic or arrhythmic death.


## REFERENCES

- Marcus F, Fontaine G, Guiraudon G, Frank R, Laurenceau JL, Malergue C, *et al.* Right ventricular dysplasia: A report of 24 adult cases. *Circulation* 1982;65:384-98.
- Ellinor PT, MacRae CA, Thierfelder L. Arrhythmogenic right ventricular cardiomyopathy (Review). *Heart Failure Clin* 2010;6:161-77.
- Thiene G, Nava A, Corrado D, Rossi L, Pennelli N. Right Ventricular Cardiomyopathy and sudden death in young people. *N Engl J Med* 1988;318:129-33.
- Hulot JS, Jouven X, Empana JP, Frank R, Fontaine G. Natural history and risk stratification of arrhythmogenic right ventricular dysplasia/cardiomyopathy. *Circulation* 2004;110:1879-84.
- Marcus FI, McKenna WJ, Sherrill D, Basso C, Bauce B, Bluemke DA, *et al.* Diagnosis of Arrhythmogenic Right Ventricular Cardiomyopathy/ Dysplasia: Proposed Modification of the Task Force Criteria. *Circulation* 2010;2:1533-41.
- Thiene G, Corrado D, Basso C. Arrhythmogenic right ventricular cardiomyopathy / dysplasia (Review). *Orphanet J Rare Dis* 2007;2:1-16.

**Source of Support:** Nil, **Conflict of Interest:** None declared.

### Announcement

#### Android App



A free application to browse and search the journal's content is now available for Android based mobiles and devices. The application provides "Table of Contents" of the latest issues, which are stored on the device for future offline browsing. Internet connection is required to access the back issues and search facility. The application is compatible with all the versions of Android. The application can be downloaded from <https://market.android.com/details?id=comm.app.medknow>. For suggestions and comments do write back to us.