

Ultrasound Evaluation in Various First Trimester Abortions

1. Dr Sartaj Khan Saheblal Pathan, 2. Dr Pathan Minhaj Saheblal

Corresponding Author Dr Sartaj Khan Saheblal Pathan*

Abstract

Aim: To evaluate sonographic features of complications related to first trimester pregnancy like different types of abortion, by trans abdominal and trans vaginal study.

Methodology: Prospective study conducted in 149 patients referred to the Department of Radiodiagnosis, Pushpagiri Institute of Medical Sciences & Research Center, Tiruvalla for

antenatal sonography for a period of two years.

Method of Data Collection: Data for the study was collected by pre-prepared case proforma which included detailed clinical history, physical examination findings and USG findings.

Conclusion: The present study confirms the role of ultrasound in early pregnancy and its complications since it gives a definitive diagnosis of early pregnancy and is invaluable in assessing fetal viability.

Keywords: abortion, first trimester, ultrasound.

Introduction

Ultrasound examination performed in early pregnancy yields many valuable informations. Like confirming an intra uterine pregnancy, establishes accurate dating, and is crucial in diagnosing early pregnancy failure and ectopic pregnancy.

The occurrence of vaginal bleeding in the first trimester of pregnancy is estimated to be as high as 25% of all pregnancies. Estimates suggest that approximately one half of these pregnancies will continue and one half will miscarry. In these women who present with bleeding per vagina during their first trimester, several diagnostic possibilities can be considered. By mere clinical examination and history definitive diagnosis is usually impossible. The causes of bleeding are many and cover a spectrum of conditions ranging from a viable pregnancy to non-viable pregnancy.

Materials and Method

All the 149 patients were referred to the Department of Radiodiagnosis, Pushpagiri Institute of Medical Sciences & Research Center, Tiruvalla for antenatal sonography for a period of two years

All women in first trimester pregnancy with lower abdominal pain or bleeding per vagina referred for emergency ultrasound and all the women with incidentally detected abnormalities during routine first trimester antenatal scan were included in the study. Women in second and third trimester of pregnancy and asymptomatic women in first

trimester pregnancy with normal antenatal scan were excluded from the study.

Equipment Ultrasonography

1. GE Systems Logic 5, 2. Philips HD 11, 3. GE Systems Logic 3 Expert, 4. Mindray DC -7
Any of the above USG Scanners was used as per availability.

Imaging Protocol

Ultrasound evaluation of the female pelvis is conducted with a real-time scanner, preferably using a sector or curvilinear transducer. The scanner is adjusted to operate at the highest clinically appropriate frequency, realizing that there is a trade-off between the resolution and beam penetration.

Trans abdominal studies were performed with fully distended urinary bladder using 3.5 MHz sector transducer.

The sector probe was placed in the supra pubic area over the bladder and was angled caudally to obtain longitudinal section of the uterus, cervix and vagina. Then the orientation was changed to transverse, to study the adnexal regions by angling the probe gently from caudal to cranial end by about 15° to 20°. While doing so vaginal walls, cervix

and body of the uterus were studied.

Transvaginal scanning was then performed with the patient's consent after the patient had fully voided. In selected cases where transabdominal study was inconclusive due to inadequately full maternal urinary bladder, obesity, inadequate visualisation of the embryo or the gestational sac, unusual uterine configuration or uterine mass etc. transvaginal scan provided additional information. Transvaginal probes insonate at higher frequencies of 7-12 MHz. For transvaginal scan the patient was placed in the lithotomy position having emptied her bladder.

The transvaginal probe was covered with a protective sheath, usually a condom and adequate coupling gel is applied. The transducer was inserted into the vagina. Initially a longitudinal scan was done followed by a transverse scan.

During examination, the size, shape, version of the uterus was noted. The presence or absence of the gestational sac is recorded to confirm early pregnancy. The size, shape and its measurements were taken to obtain the mean sac diameter. In cases where gestational sac was present, presence or absence of fetal pole and yolk sac were recorded. If the sac was empty, its shape and gestational age were calculated. If the fetal pole was seen, then it was observed for fetal cardiac activity, movements and any obvious abnormalities.

Depending on the observation, appropriate measurements of gestational age were obtained i.e., CRL or BPD.

Patients in whom scan was done late in first trimester, location of placenta, its maturity and evidence of hemorrhage if any were noted.

In cases where relevant, cervical length was measured and the status of cervical internal

Incomplete Complete Missed Inevitable Threatened

Abortion Abortion Abortion Abortion
as was documented.

Finally, the adnexal region was assessed to confirm or rule out ectopic pregnancy and also to look for ovarian masses. Presence or absence of free fluid in the pouch of Douglas or pelvis is also documented.

Follow up ultrasound was performed whenever indicated. All the cases with various

complications were followed up and the rest with normal pregnancy were managed accordingly.

Observations and Results

In the present study, out of 146 cases, majority (42%) were abortions. Among these the distribution pattern was as follows: Threatened abortion - 14%, Incomplete abortion - 13%, Missed abortion – 5.5%, Inevitable abortion – 5%, Complete abortion – 5%

Out of the 21 (14%) cases diagnosed to be threatened abortion, 16 cases were found to have sub chorionic hemorrhage. Of these 7 cases had large sub chorionic bleed, almost all of which eventually underwent spontaneous expulsion or dilatation & evacuation. Those cases that had only a small sub chorionic bleed, majority (66.6%) were followed up to have a normal pregnancy. 2 cases had gestational sac which was small for gestational age. Rest of the 3 cases had an enlarged yolk sac.

All the 19 cases of incomplete abortion demonstrated heterogeneous endometrial collection, with varying degrees of vascularity within it, suggestive of retained products of conception. They underwent surgical intervention in the form of dilatation & evacuation

In the present study, there were 8 cases of missed abortion. Evidence of fetal pole without cardiac activity was noted in all of them. Of these, 5 cases were treated conservatively as they underwent spontaneous expulsion. Rest of them had surgical intervention.

All the 7 patients who were diagnosed as complete abortion on ultrasound were treated conservatively.

Table1; Distribution of Cases Based on Clinical Diagnosis

Clinical Diagnosis	No. of cases	Percentage
Threatened Abortion	58	39.72
Incomplete Abortion	26	17.80
Complete Abortion	15	10.27
Ectopic Pregnancy	26	17.80
Missed abortion	6	4.10
Inevitable Abortion	15	10.27
Total	146	

Fig:1

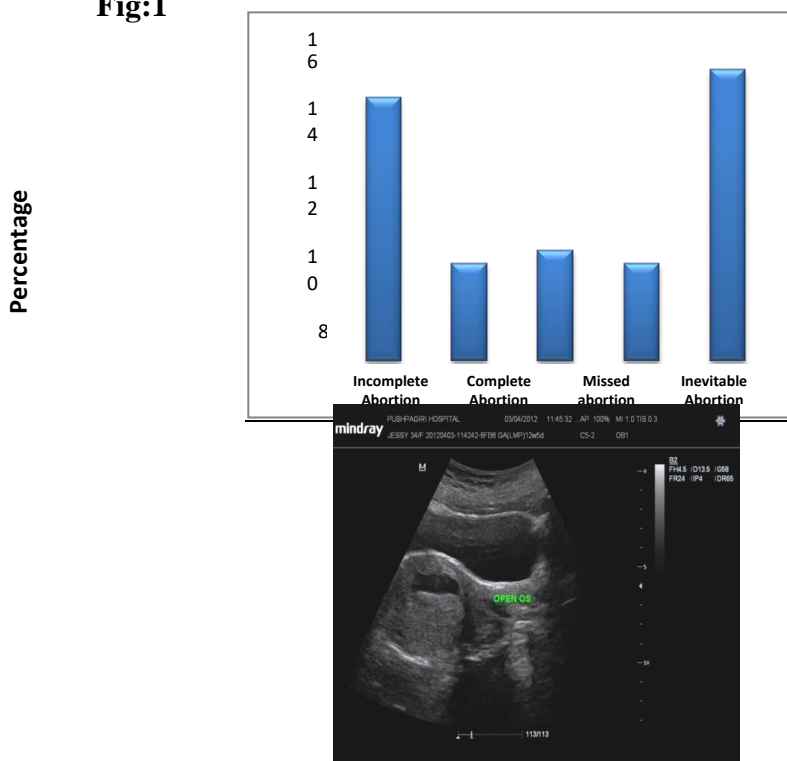


Fig2:TAS- Internal os was open with fluid within cervical canal – consistent with inevitable abortion

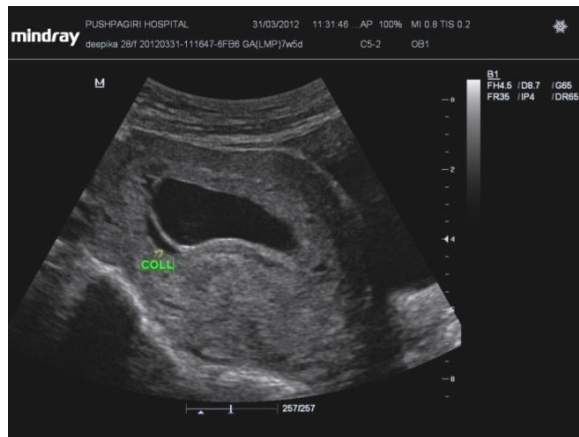

Fig3: Small Subchorionic collection noted at inferior aspect of the gestational sac.

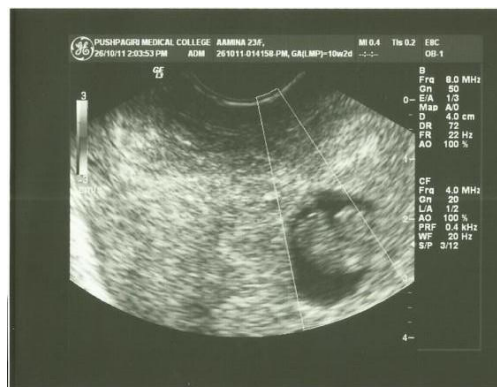

Fig 4: TVS Absent cardiac activity for the given CRL is suggestive of a Missed abortion. Fig3: TVS

Discussion Threatened abortion

In the present study, out of 146 cases, 21 (14%) cases were diagnosed to be threatened abortion. 16 of these cases were found to have sub chorionic hemorrhage detected by only ultrasonography. Of these 7 cases had large subchorionic bleed, almost all of which eventually underwent spontaneous expulsion or dilatation & evacuation. Of

the 9 cases that had only a small sub chorionic bleed, 6 cases were followed up to have a normal pregnancy.

The diagnosis of subchorionic hemorrhage by ultrasound gives a further prognosis of the outcome. Thus, ultrasound is an accurate method for evaluating threatened abortion

because it can readily demonstrate presence or absence of embryonic cardiac activity. Genevieve L. Bennet et al (1) found in a retrospective study of 516 patients with first trimester bleeding, to determine the effects of subchorionic hematoma size, gestational age, and maternal age on pregnancy outcome in patients with vaginal bleeding. They found that an overall pregnancy loss of 9.3%. this increases with increasing maternal age and decreasing MA. Their most important criteria was the size of the bleed. The small or medium sized ones (1/3 rd or 1/2 of the sac circumference) have a miscarriage rate of 9% as compared with 18.8% for the larger ones.

Subchorionic hemorrhage is seen on ultrasound in 4% to 22% of patients who have symptoms of pain and bleeding in early pregnancy. (2)

Nagy S et al (3) studied 7862 women who underwent routine first-trimester ultrasound examinations. Intrauterine hematomas occur in 3.1% of a general obstetric population and are associated with adverse pregnancy outcome irrespective of the presence of symptoms of

Conclusion

Ultrasound plays a major role in early detection of pregnancy and its complications since clinical history and pelvic examination are inadequate in assessing the cause and the prognosis. Ultrasound is a noninvasive, non-ionizing, cheap, easily available and reproducible method of investigation to assess the patients in first trimester of pregnancy. Ultrasound adequately evaluates the status of the uterus, cervix, internal os, adnexa, gestational sac, fetal pole and presence of cardiac activity. Thus it guides the clinician in choosing the appropriate line of management and prevents mismanagement of the cases. Along with trans abdominal study, a transvaginal ultrasound should also be done in patients presenting with complications, as TVS reliably identifies various normal and abnormal findings at an earlier stage than TAS.

References

1. Bennet GL, Bromley B, Leiberman E et al. Subchorionic hemorrhage in first trimester pregnancies: Prediction of pregnancy outcome with sonography. Radiology 1996;200:803-806.
2. Pearlstone M, Baxi L. Subchorionic hematoma: a review. Obstet Gynecol Surv 1993;48:65–8.
3. Nagy S, Bush M, Stone J, Lapinski RH, Gardo S. Clinical significance of retroplacental hematomas detected in the first trimester of pregnancy. Obstetrics & Gynaecology 2003;102:94-100.
4. Bryann Bromley, Bernard L. Harlow, Lane A. Laboda, Beryl R. Benacerraf, Small Sac Size in the First Trimester: A Predictor of Poor Fetal Outcome.
5. Daniel J. Lindsay, Ian S. Lovett, Edward A. Lyons, Clifford S. Levi, Xin-Hua Zheng, Susan C. Holt et al. Yolk Sac

Diameter and Shape at Endovaginal US: Predictors of Pregnancy Outcome in the First Trimester

6. Gezer, A. et al. Early first trimester ultrasound examination. Is it really efficient in the clinical management of the pregnancy? Archives of Gynecology and

