

"MORPHOMETRIC AND COMPUTER TOMOGRAPHIC STUDY OF FORAMEN OVALE"

Dr. Ragini Yadav¹, Dr. Areeba Nasar², Dr. Rahul Srivastava³, Dr. Vandana Tewari⁴

1. Dr. Ragini Yadav

PG Student, Rama University, Kanpur

Email: raginiyadav@gmail.com (*Corresponding Author*)

2. Dr. Areeba Nasar

Associate Professor, Rama University, Kanpur

3. Dr. Rahul Srivastava

Assistant Professor, Rama University, Kanpur

4. Dr. Vandana Tewari

Professor and Head of the Anatomy Department, Rama University, Kanpur

FORAMEN OVALE

INTRODUCTION

The foramen ovale is an opening in the greater wing of the sphenoid bone. The foramen ovale is one of two cranial foramina in the greater wing, the other being the foramen spinosum. The foramen ovale is posterolateral to the foramen rotundum and anteromedial to the foramen spinosum. Posterior and medial to the foramen is the opening for the carotid canal. The following structures pass through foramen ovale-mandibular nerve, accessory meningeal artery, lesser petrosal nerve an emissary vein connecting the cavernous sinus with the pterygoid plexus.

The foramen ovale is used for different surgical and diagnostic procedures like fine needle aspiration via transfacial approach, to dignose squamous cell carcinoma, meningioma, and the spread of the tumors. It is also used for electroencephalographic analysis of of the seizure for patients, trigeminally

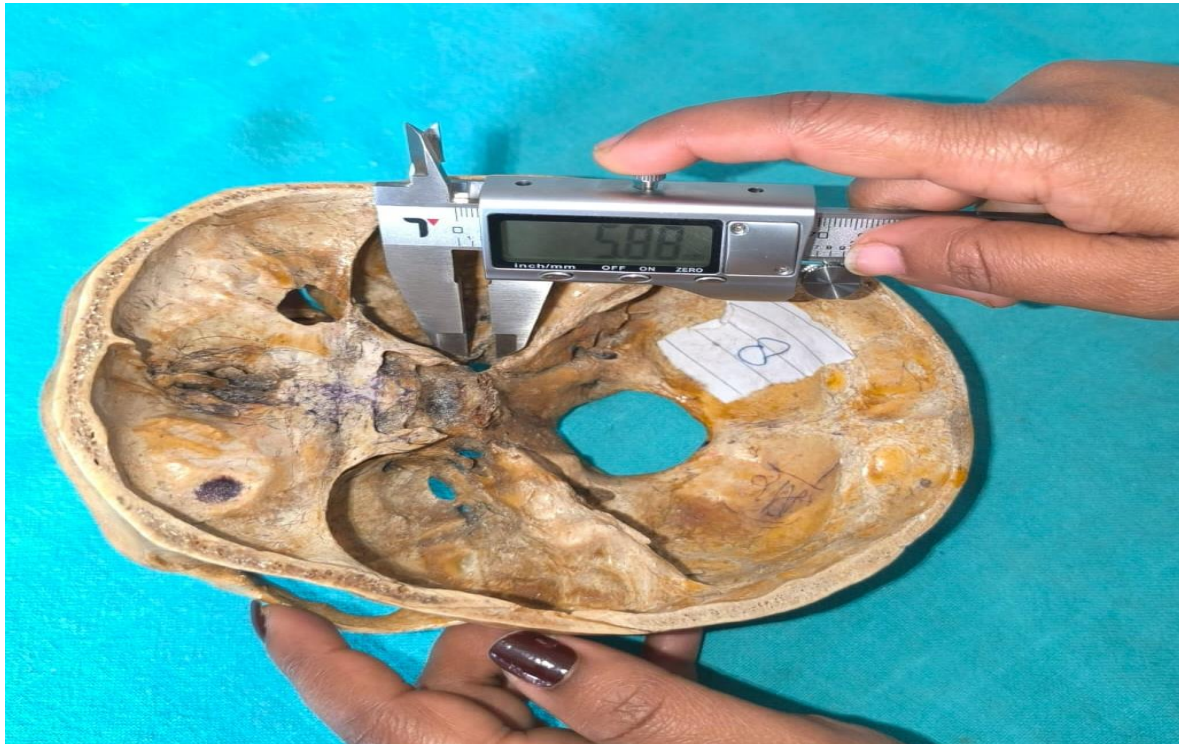rhizotomy for trigeminal neuralgia by percutaneous approach. The administration of anesthesia via mandibular nerve can be done after a thorough knowledge of the morphometry of the foramen ovale. The percutaneous biopsy of the cavernous sinus can be done through foramen ovale.

MATERIALS AND METHODS

Our study is performed on 50 dry human skulls of unknown gender and 100 CT Scans images with unknown sex in which 50 males and 50 females were taken. Dry skulls were obtained from the Department of Anatomy and CT scan images from the Department of Radiology, Rama Medical College and Hospital & Research Centre, Mandhana Kanpur. All measurements are taken from Digital Vernier Caliper.

METHODS

To examine the anteroposterior, transverse diameter and shape of Foramen Ovale.



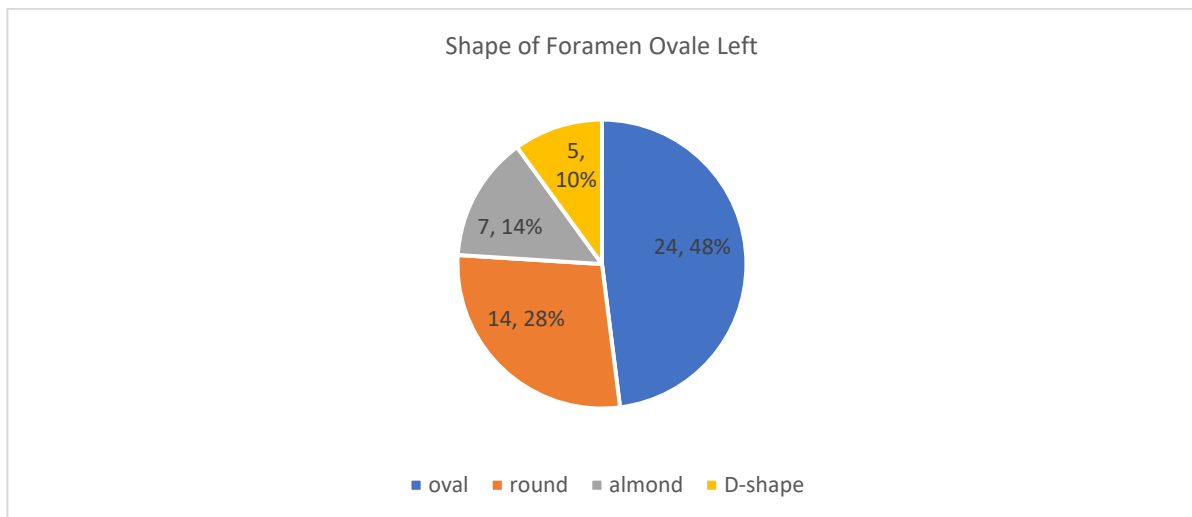
RESULT-

In our present study we observed the most common shape of foramen ovale on left side is oval shape which is found in 48% rest shape are round (28%), almond (14%), D- shape (10%). description given table number 1

Table 1 showing the shape of foramen ovale on left side

S.no.	Shape of foramen	Numberof shapes	Percentage
1	Oval	24	48%
2	Round	14	28%

3	Almond	7	14%
4	D-shape	5	10%

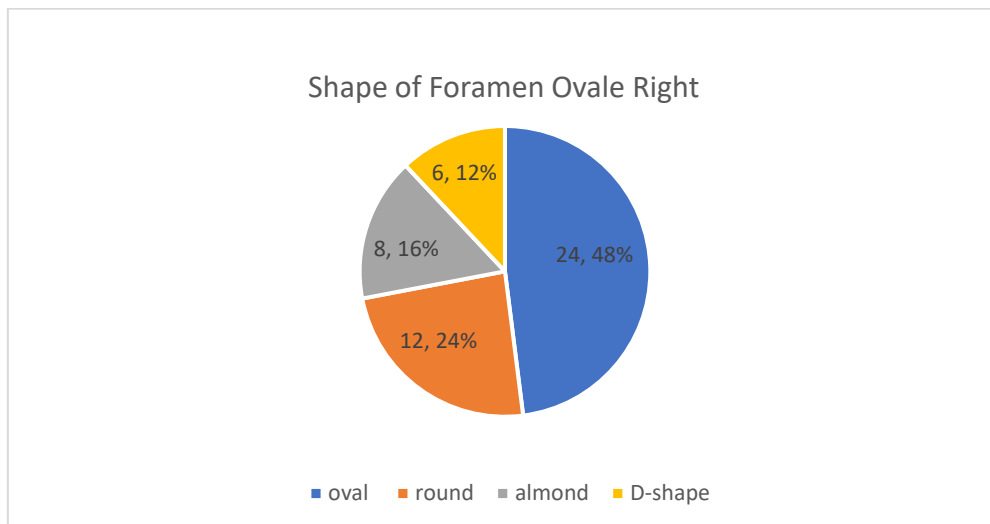


Pie chart number 1 showing the shape of foramen ovale on left side

In our present study we observed the most common shape of foramen ovale on right side is oval shape which is found in 48% rest shape are round (24%),almond(16%),D- shape(12%). Description given table number 2.

Table 2 showing the shape of foramen ovale on right side

Shape of foramen	Number of shapes	Percentage
Oval	24	48%
Round	12	24%
Almond	8	16%
D-shape	6	12%

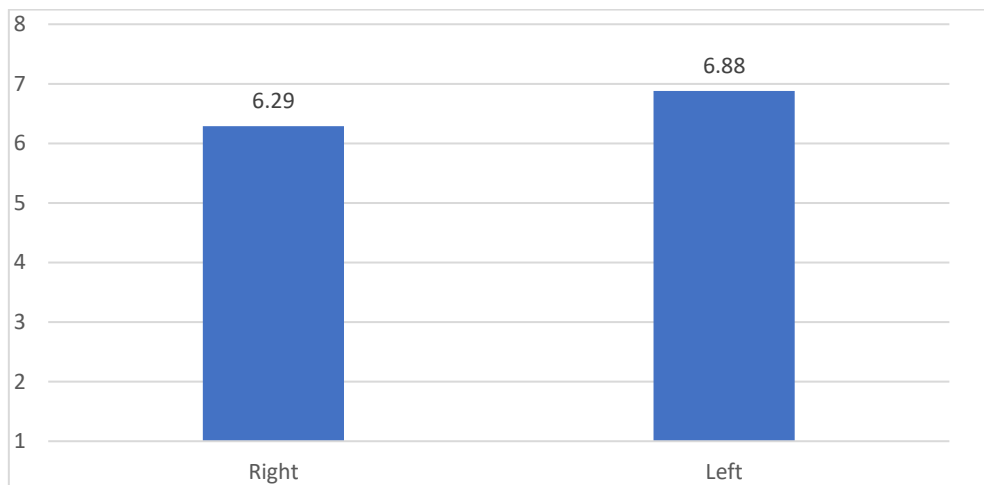


Pie chart number 2 showing the shape of foramen ovale on right side

In our current study we observed that the mean anteroposterior of foramen ovale is 6.29 mm on left side and 6.88 mm on right side (which p value is significant on left and right side). The descriptive statistical value as shown in Table number 3.

**Table number 3 showing descriptive static value of the anteroposterior of
Foramen ovale**

Side	Mean	Std. Deviation	Std. Error Mean	T value	Degree of Freedom	P value
Right	6.29	1.15	.16	2.71	98	0.008
Left	6.88	1.01	.14		96.57	

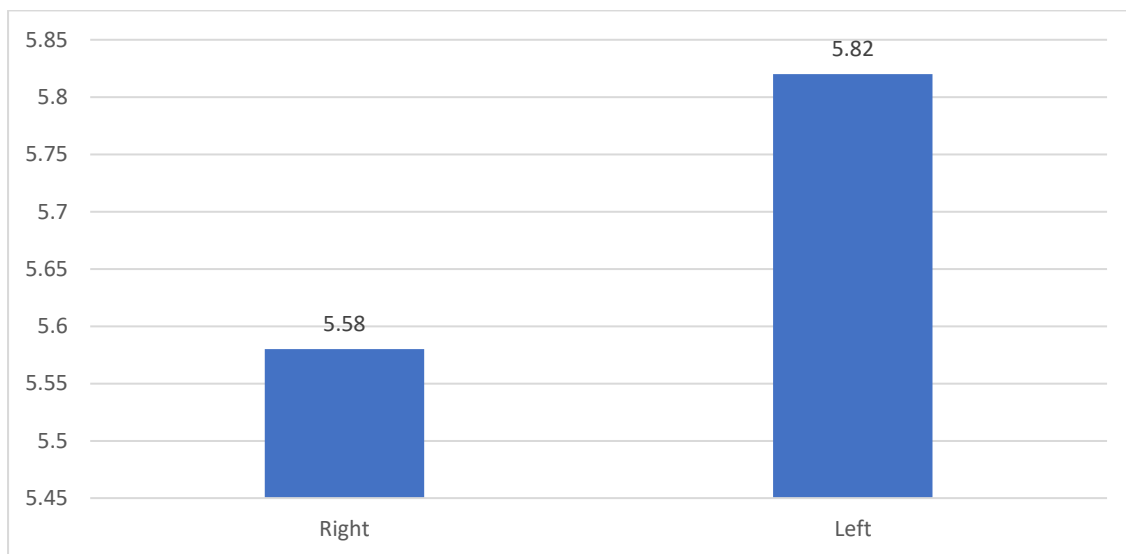


**Bar Graph number 1 showing the mean value of anteroposterior of
foramen ovale on right and left side**

In our current study we observed the mean transverse diameter of foramen ovale is 5.82 mm on left side and 5.58 mm on right side (which p value is non-significant on left and right side). The descriptive statistical value show in Table number 4.

**Table number 4 showing descriptive static value of the transverse diameter
of Foramen ovale**

Side	Mean	Std. Deviation	Std. Error Mean	T value	Degree of Freedom	P value
Right	5.58	1.48	.21	.818	98	0.415
Left	5.82	1.45	.20		97.93	

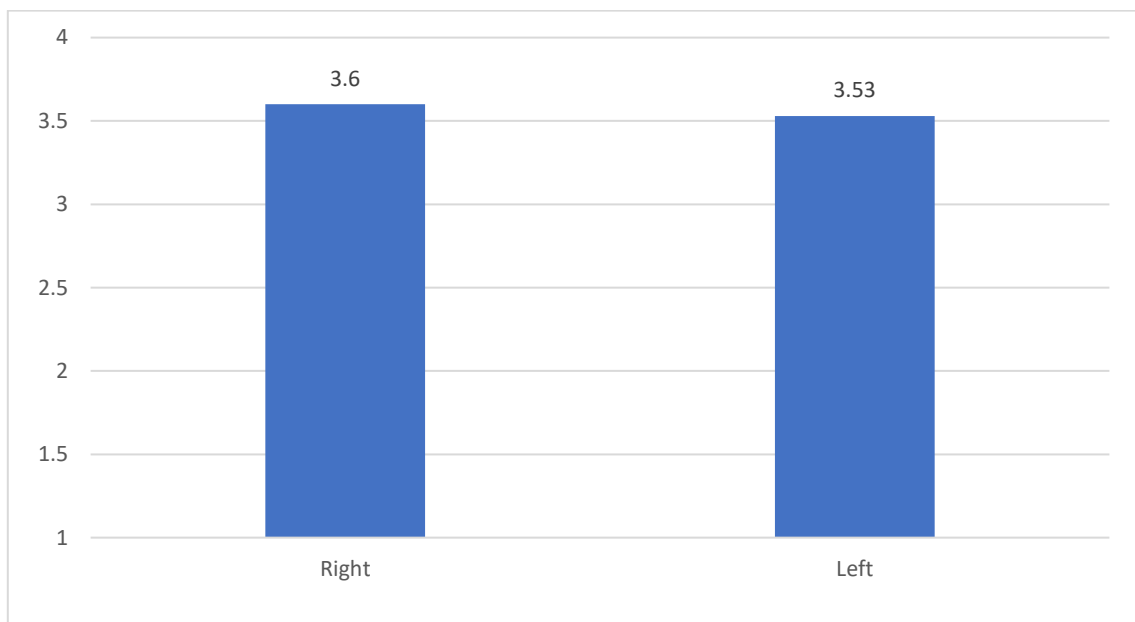


**Bar Graph number 2 showing the mean value of transverse diameter of
foramen ovale on right and left side**

In our radiological study we observed the mean anteroposterior diameter of foramen ovale is 3.53 on left side and 3.60 on right side. Description is given table number 5

Table number 5

Side	Mean	Std. Deviation	Std. Error Mean	T value	Degree of Freedom	P value
Right	3.60	.84	.084	0.592	198	0.554
Left	3.53	.73	.073		193.947	

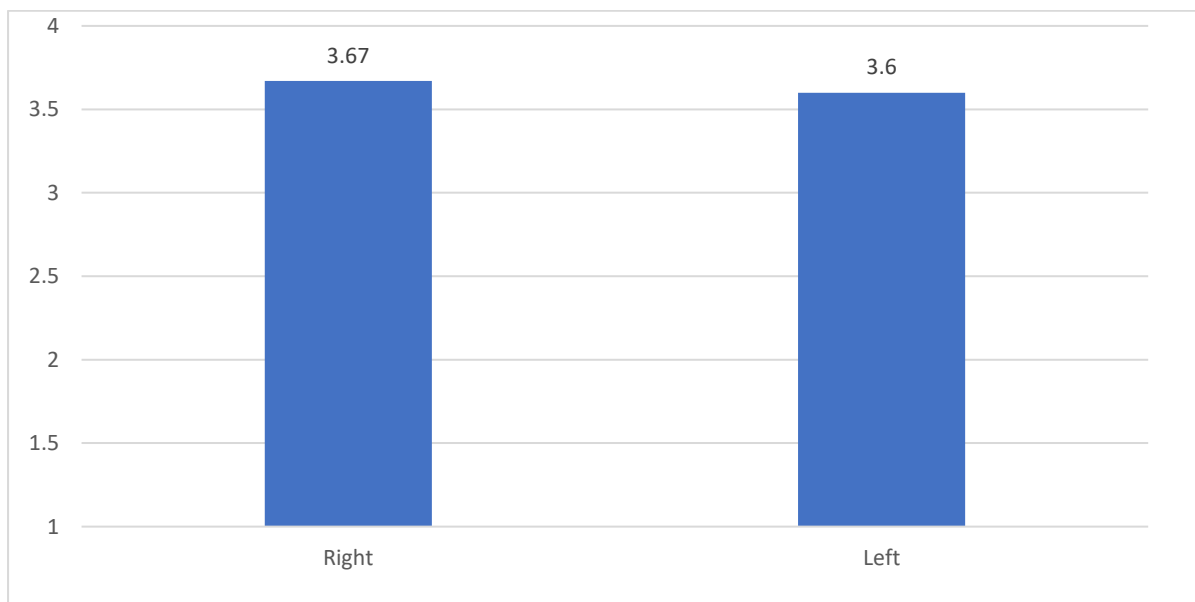


Bar graph number 3 is showing mean value of anteroposterior foramen ovale on right and left side

In our radiological study we observed the mean transverse diameter of foramen ovale is 3.60 on left side and 3.67 on right side. Description is given table number 6.

Table number 6

Side		Mean	Std. Deviation	Std. Error Mean	T value	Degree of Freedom	P value
Right		3.67	.77	.07	0.613	198	0.540
Left		3.60	.78	.078		197.990	



Bar graph number 4 is showing mean value of transverse diameter of foramen ovale on right and left side

DISCUSSION-

FORAMEN OVALE (ANTEROPOSTERIOR)-

In our present study we observed that the mean anteroposterior of foramen ovale is 6.29 mm on left side and 6.88 mm on right side (which p value is significant on left and right side) and in our radiological study we observed the mean anteroposterior diameter of foramen ovale is 3.53mm on left side and 3.60mm on right side. While comparing our study with **Supriya Garapati et al** who performed the study on 100 foramen ovale using 50 dry adult human skull bones of unknown sex and remarked that the mean anteroposterior diameter on left side was 6.59 ± 1.37 mm and on right side was 6.99 ± 1.44 mm another study of **Das Saurjyaranjan et al** observed 50 human dry skull of unknown sex and age and found that the maximum anterior posterior diameter was found to 9.8mm on right side and 9.6mm on left side. The mean anterior posterior diameter on right side was 7.11 ± 1.688 and on the left was 6.53 ± 1.333 . another study of **Jyothsna Patil et al** observed that the mean antero-posterior length of foramen ovale was 7.0 ± 2.17 mm on right side and 6.8 ± 1.40 mm on left side. another study of **Zahra Haider Bokhari et al** worked on 55 dry skulls and observed that the mean length of foramen ovale on right side was 7.04 ± 1.08 and on the left side was 7.18 ± 1.14 . another study of **Shankar et al** conducted study on Foramina of the Middle Cranial

Fossa and observed that the mean length of 6.62 ± 1.11 mm (right side) and 6.72 ± 1.08 mm (left side). There finding is similar with our finding. No such study found in previous year which conflicted with our finding.

FORAMEN OVALE (TRANSVERSE)-

In our present study we observed that the mean transverse diameter of foramen ovale is 5.82 mm on left side and 5.58 mm on right side (which p value is non-significant on left and right side) and in our radiological study we observed the mean transverse diameter of foramen ovale is 3.60 on left side and 3.67 on right side .While comparing with **Santosh et al** worked on 51 ossified adult skull and observed that the mean transverse diameter on the right side and left side was 3.58 ± 0.90 mm and 3.45 ± 0.99 mm. Another study of **Shankar et al** conducted study on Foramina of the Middle Cranial Fossa and observed that the width of 3.78 ± 0.89 mm (right side) and 3.89 ± 0.73 mm (left side) were observed. Similar study of **Supriya Garapati et al** performed the study on 100 foramen ovale using 50 dry adult human skull bones of unknown sex and remarked that the mean transverse diameter on the left is 4.09 ± 0.74 mm and 4.17 ± 0.76 mm on the right side. Similar study of **Das Saurjyaranjan et al** studied on 50 human dry skull of unknown sex and age and found that the mean transverse diameter of the foramen on right was 3.148 ± 0.686 and on the left was 3.2 ± 0.678 . Another study of **Jyothsna Patil et al** observed the mean transverse width was 5.0 ± 0.42 mm and 4.70 ± 0.91 mm on right and left side. Similar study

of **Zahra Haider Bokhari** et al worked on 55 dry skulls and the mean width of the foramen on the right side was 5.15 ± 0.92 & left side was 3.99 ± 0.86 . There finding is similar with our finding. No such study found in previous year which conflicted with our finding.

FORAMEN OVALE (SHAPE)-

In our present study we observed the most common shape of foramen ovale on left side is oval shape which is found in 48% rest shape are round (28%), almond (14%), D- shape (10%) and on right side is oval shape which is found in 48% rest shape are round (24%), almond (16%), D- shape (12%). While comparing our study with **Supriya Garapati et al** performed the study on 100 foramen ovale using 50 dry adult human skull bones of unknown sex and remarked that shapes of the foramen ovale were oval 70%, almond 11%, round 9%, elongated 6%, pear shaped 2 % and irregular 2%. Another study of **Mamatha. Y et al** conducted on One hundred (100) dry adult skulls and observed the foramen ovale like round (9%) and oval (91%) on right side and on left side it was oval in 89% and round in 11%. Similar study of **Das Saurjyaranjan et al** studied on 50 human dry skull of unknown sex and age and found the shape of the foramen was found to be oval in 70%, almond in 18%, rounded in 8% and triangular in 4%. Similar study of **K G Prakash et al** worked on 82 adult skulls and observed that the shape of foramen was typically ovale in most of the skulls (56.70%) with some bony variations such as spine,

tubercles, bony bridge/bar and confluence. Similar study of **Poornima b. et al** observed 200 sides in 100 adult dry human skull and found Oval shaped foramina were 60%, almond shape were 25%, round shape were 13% and slit like foramina were 2%. 11% of foramina had spines, 5% had tubercles and 10% had a bony plate. Another study of **M.S Somesh et al** studied on 82 adult skulls and found the shape of foramen was typically ovale in most of the skulls (56.70%). There finding is similar with our finding. No such study found in previous year which conflicted with our finding.

CONCLUSION-

Osteological Findings

In the osteological examination, significant variations in dimensions were observed between the left and right sides of all cranial foramina. The mean anteroposterior diameter of the foramen ovale measured 6.29 mm on the left and 6.88 mm on the right, while the transverse diameter measured 5.82 mm on the left and 5.58 mm on the right. These findings indicate that the foramen ovale is slightly larger on the right side in terms of its anteroposterior dimension but exhibits a reduced transverse diameter compared to the left side.

Radiological Findings

Radiological measurements revealed smaller dimensions for all cranial foramina compared to osteological findings, likely due to the influence of soft tissues,

imaging resolution, and technical limitations inherent in radiological methodologies. For the foramen ovale, the mean anteroposterior diameter measured 3.53 mm on the left and 3.60 mm on the right, while the transverse diameter was 3.60 mm on the left and 3.67 mm on the right. These measurements underscore a consistent pattern of the right side being marginally larger in both dimensions.

Reference-

1. Jyothsna Patil, Naveen Kumar, Mohandas Rao K.G, Swamy Ravindra S, Somayaji S N, Satheesha Nayak B, Sapna Marpalli, Ashwini L.S. The Foramen Ovale Morphometry of Sphenoid Bone in South Indian Population. Journal of Clinical and Diagnostic Research. 2013;7(12):2668-2670
2. Naqshi1 Farooq B , Shah2 AB, Gupta S Variations in Foramen Ovale and Foramen Spinosum in Human Skulls of North Indian Population International Journal of Contemporary Medical Research ISSN (Online): 2393-915X; (Print): 2454-7379 | ICR: 77.83.
3. Ominde, Shitandi B; Eruwu D B; Ikubor, Joyce Ekeme1; Omoro, Faithful Orovwohene; Igbigbi, Patrick Sunda A computed tomography-based retrospective study on the foramen ovale and foramen spinosum in a Nigerian population DOI: 10.4103/mgmj.mgmj_277_23 june 2024

4. Kenan O, Veysel Atilla AY, Ahmet DYadigar KAn Investigation of the Morphometry and Localization of the Foramen Ovale and Rotundum in Asymptomatic Individuals and Patients with Trigeminal Neuralgia DOI: 10.5137/1019-5149.JTN.33760-21.3.
5. Ominde, Shitandi B; Eruwu D B; Ikubor, Joyce Ekeme1; Omoro, Faithful Orovwohene; Igbigbi, Patrick Sunda A computed tomography-based retrospective study on the foramen ovale and foramen spinosum in a Nigerian population DOI: 10.4103/mgmj.mgmj_277_23 june 2024
6. Prakash KG, Saniya K, Honnegowda TM, Ramkishore HS, Nautiyal A. Morphometric and Anatomic Variations of Foramen Ovale in Human Skull and Its Clinical Importance. Asian J Neurosurg. 2019 Nov 25;14(4):1134–7
7. Rao BS, YesenderM,Vinila S H B morphological variations and morphometric analysis of foramen ovale with its clinical implications DOI: <https://dx.doi.org/10.16965/ijar.2016.487>.
8. SaurjyaranjanD,SC, Gyanaranjan N an anatomical study of foramen ovale with clinical implications DOI: <https://dx.doi.org/10.16965/ijar.2018.375>.
9. Shankar G, Muthukumaravel N. A morphological and morphometric study of FO in dry skulls of Indian population. National Journal of Clinical Anatomy. 2019;8(1):3

- 10.Somesh MS, Sridevi HB, Prabhu LV, Gangadhara Swamy MS, Krishnamurthy A, Murlimanju BV, et al. a morphometric study of foramen ovale. Turkish Neurosurgery. 2011; 21(3): 378-83