

Journal of Cardiovascular Disease Research

An Official Publication of SciBiolMed.Org (A publishing division of Phcog.Net)

"Our mission, Your Outstanding Research Work"

Volume 7, Issue 1, Jan-Mar, 2016

About Journal

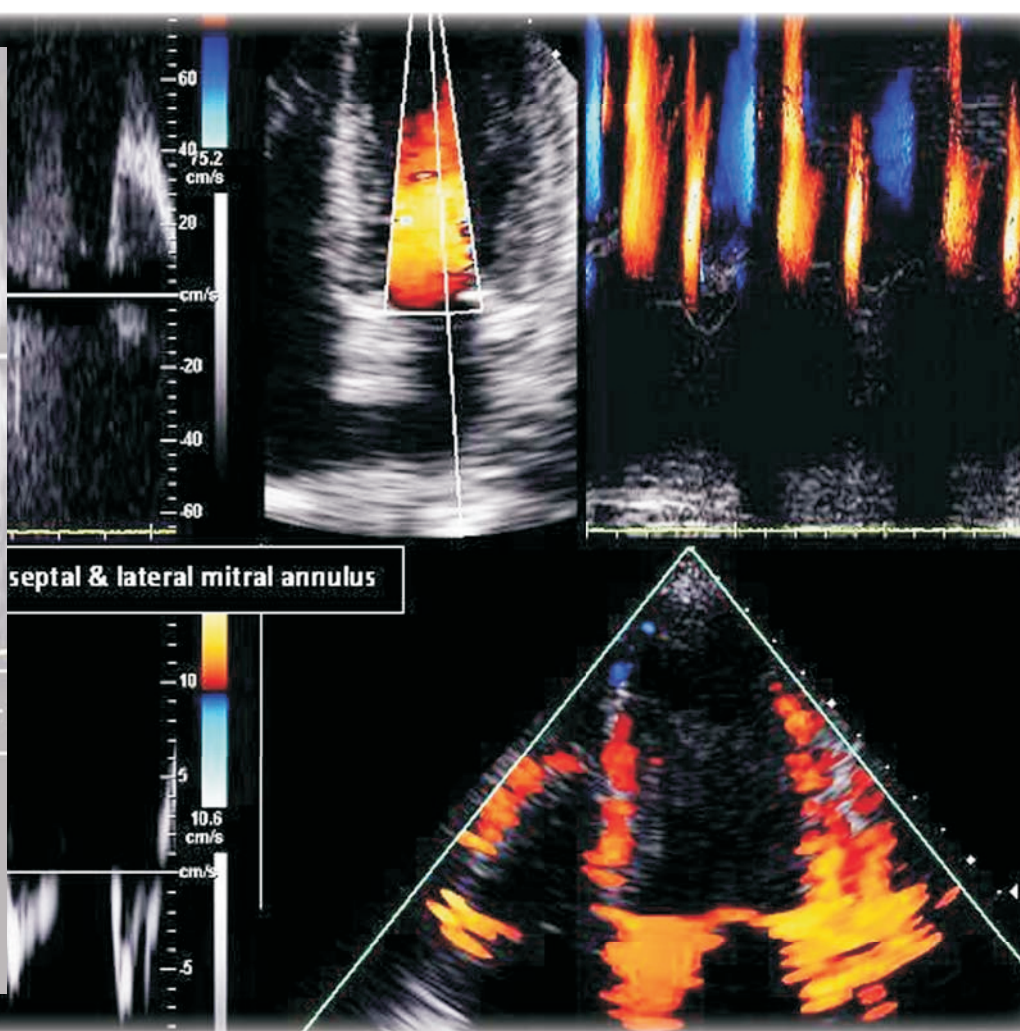
Journal of Cardiovascular Disease Research (J Cardiovasc. Dis. Res.)

[www.jcdronline.org]

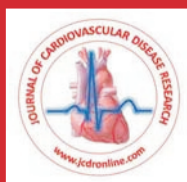[ISSN: Print -0975-3583, Online - 0976-2833]

An official publication of SciBiolMed.Org (www.scibiolmed.org);

it is a double-blind peer-reviewed, open access international circulating professional journal led by a group of research scientists, vascular disease experts and cardiologists coming from North America, Asia and Europe etc.



Indexed and Abstracted in : The journal is indexed with Caspur, Chemical Abstracts, CNKI (China National Knowledge Infrastructure), DOAJ, EBSCO Publishing's Electronic Databases, Expanded Academic ASAP, Genamics JournalSeek, Google Scholar, Health & Wellness Research Center, Health Reference Center Academic, Hinari, Index Copernicus, MANTIS, OpenJGate, PrimoCentral, ProQuest, Scimago Journal Ranking, SCOLAR, SCOPUS, SIIC databases, Summon by Serial Solutions and Ulrich's International Periodical Directory



JCDR - Providing Cutting Edge Research information on Cardiovascular Diseases

Senior International Editor: Dr. Dayi Hu
Editor : Dr. Peng Zhou

Manuscript

Hemophilia B with Acute Myocardial Infarction-A Case Report with Brief Review of Literature

Venkatesh Tekur Krishnamurthy

Department of Cardiology, Apollo Hospital, Bannerghatta Road, Bangalore, Karnataka state, INDIA.

ABSTRACT

Hemophilia B with acute myocardial infarction is rare and presents a management challenge. Acute myocardial infarction demands restoration of blood flow to the jeopardised myocardium at the earliest. With a background of easy tendency to a major bleed in Hemophilia B, use of fibrinolytic therapy, antiplatelets, or anticoagulants are fraught with danger. A 52 year male with Hemophilia B, on regular maintenance doses of factor IX replacement, presented with acute anterior wall myocardial infarction. Patient had a history of oral bleed the previous day. His further management presented a challenge as fibrinolytic therapy or primary percutaneous intervention with stenting and subsequent use of antiplatelets and anticoagulants would invite the danger of life threatening major bleed. Patient had primary percutaneous coronary intervention under cover of one antiplatelet therapy and plain balloon angioplasty to culprit vessel was carried out with good outcomes.

Key words: Hemophilia B, Factor IX Deficiency, Acute Myocardial Infarction, Primary Percutaneous Intervention, Antiplatelets.

Key message: An emerging issue is the management of cardiovascular disease in hemophilia. The optimal management of acute myocardial infarction presents a challenge as treatment involves use of antiplatelets and anticoagulants interfering with hemostasis. A delicate equilibrium between bleeding and thrombosis needs to be achieved during cardiac intervention.

Correspondence:

Venkatesh Tekur Krishnamurthy, Department of Cardiology, Apollo Hospital, Bannerghatta Road, Bangalore 560076, Karnataka State, INDIA.

Phone no: +91 98440 75579

Submission Date: 11-01-2016; Revised date: 08-02-2016;

Accepted Date: 15-02-2016

E-mail: venkateshtekur@yahoo.com

DOI : 10.5530/jcdr.2016.1.6

INTRODUCTION

The hemophilic conditions are a group of related inherited bleeding disorders and include abnormalities of coagulation factors as well as platelet function; the most common of these disorders is von Willebrand disease. Hemophilia A and B are X-linked recessive diseases that present in male children of carrier females. When the term "hemophilia" is used, it most often refers to one of the following two disorders: Factor VIII deficiency (hemophilia A) and Factor IX deficiency (hemophilia B, Christmas disease). Hemophilia B occurs in approximately 1 in 30,000 live male births. Approximately half have severe disease (ie, factor IX activity <1 percent of normal). Hemophilia B patients may develop many age-related co-morbidities like cardiovascular disease, malignancy, osteoporosis, renal disease etc; This is because of the improved lifespan of patients with Hemophilia B. The Authors present here a patient with severe Hemophilia B who was managed for Acute Myocardial Infarction with primary percutaneous coronary angioplasty without stenting with good results.

CASE HISTORY

A 52-Year-old-male being managed for Hemophilia B with Factor IX replacement for more than two decades presented with severe chest discomfort, and sweating of one hour duration. He had a history of oral bleed the previous day. His ECG showed ST-elevation in anterior chest leads suggestive of acute anterior myocardial infarction. (Figure 1). He also had haemophilic arthropathy with restriction of movement of right elbow. Screening tests of hemostasis, including the PT, aPTT and platelet count with estimation of Factor IX levels were carried out. aPTT was prolonged with a normal PT and platelet count. The Factor IX level was less than 1%. He was started on intravenous Anti-Hemophilic Factor IX (AIMAFIX)-bolus dose of 80 U/Kg to achieve a peak Factor IX target level of >80 U/dl and was taken for coronary angiogram within one hour.

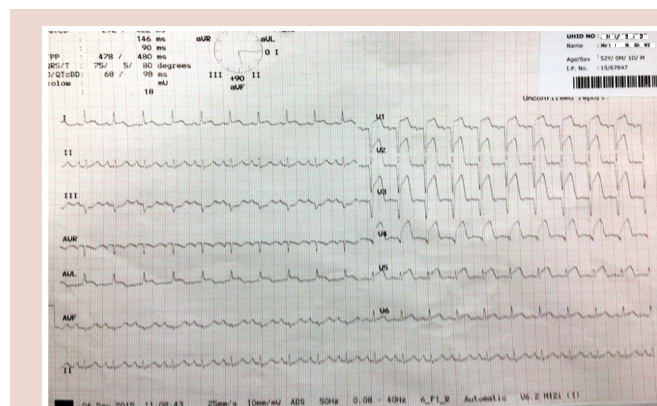


Figure 1: ECG showing ST-elevation in anterior chest leads suggestive of acute anterior myocardial infarction

One antiplatelet Tab Aspirin 100 mg was orally administered. Coronary angiogram was carried out from the left radial route as patient had restriction of movement of right elbow due to haemophilic arthropathy. (Figure 2) Coronary angiogram showed 100% cut-off of Mid Left Anterior Descending artery with a thrombus. (Figure 3). A plain balloon angioplasty (POBA) to the mid LAD lesion was carried out with excellent results and TIMI Grade 3 flow. No stent was implanted in view of excellent angiographic outcome.(Figure 4). Post POBA ECG showed satisfactory resolution of ST-Segment elevations in the anterior leads. (Figure 5). Patient was discharged uneventfully after three days and advised to continue enteric-coated Aspirin 150 mg daily once after food. The patient was advised to continue Factor IX replacement therapy as advised by his haematologist.

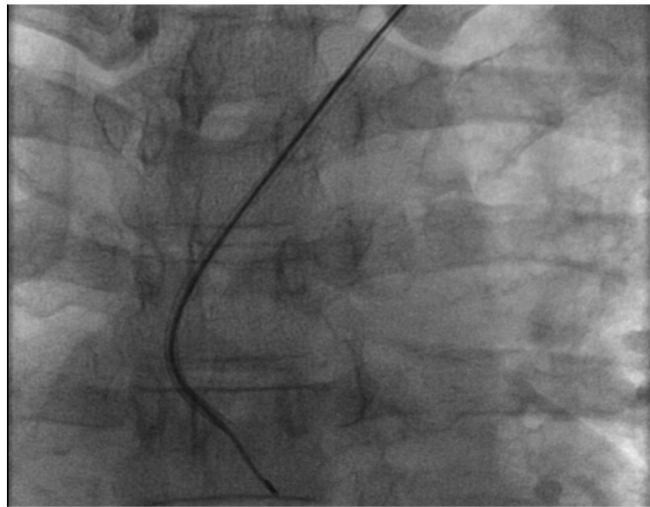


Figure 2: Coronary angiogram from the left radial route due to haemophilic arthropathy of right elbow

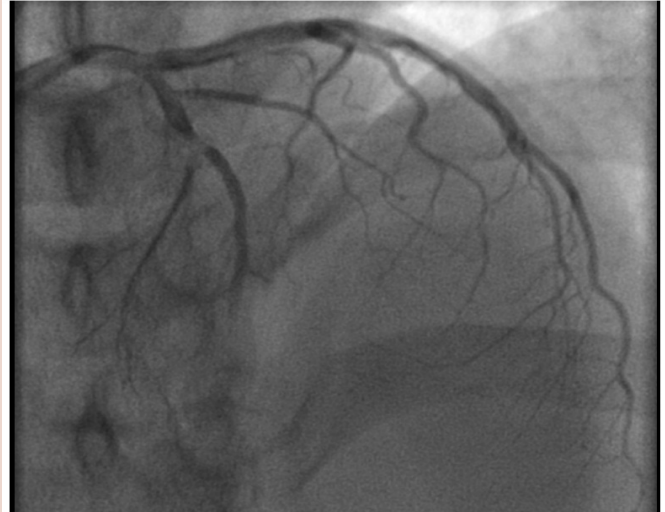


Figure 3: Coronary angiogram showed 100% cut-off of Mid Left Anterior Descending artery with a thrombus

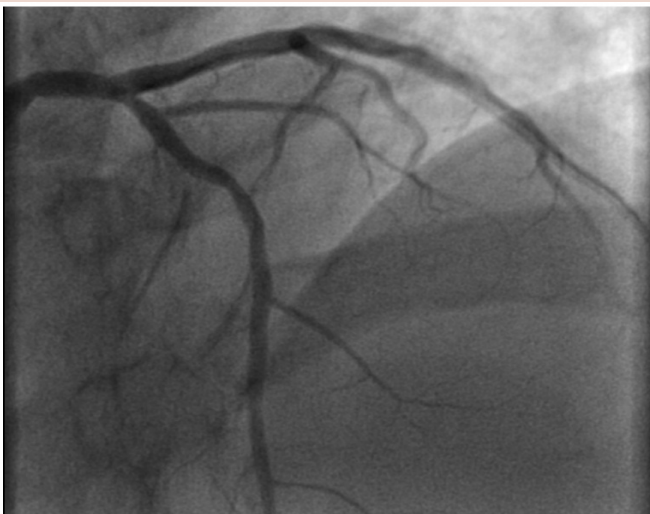

Figure 4: Excellent angiographic outcome with balloon angioplasty. No stent implanted

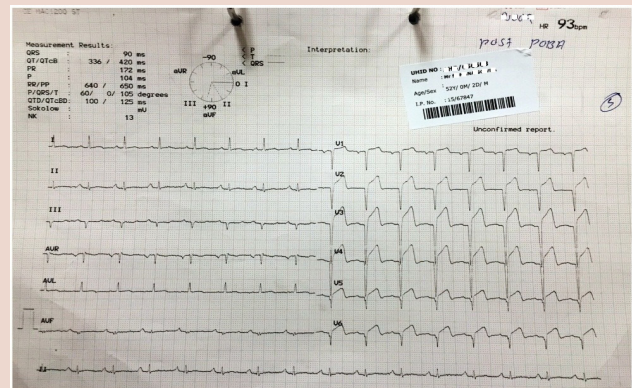


Figure 5: Post balloon angioplasty ECG showing satisfactory resolution of ST-Segment elevations in the anterior leads

DISCUSSION

About 100 years ago the median life expectancy of a person with severe hemophilia was less than 12 years of age.¹ The wide availability of safe clotting factor concentrates led to a significant increase in life expectancy and the latest UK data showed persons with severe haemophilia to have a median survival of 63 years whereas patients with mild hemophilia had a median survival of 75 years.² More and more people with severe hemophilia reach old age thanks to an effective treatment. Although mortality in individuals with hemophilia is 2 to 3-fold higher than the general population, ischemic heart disease mortality is 50–80% lower than the general population.^{2–6} Acute coronary syndromes and non valvular atrial fibrillation (AF), are the most frequent cardiovascular diseases in elderly persons with severe haemophilia, as they are in the population at large.⁷ Hemophilia carriers whose Factor VIII levels are low, but not deficient, also appear to have low death rates of ischemic cardiac disease.⁸ The tra-

ditional risk factors for ischemic heart disease in the general population, such as hypertension, diabetes mellitus and hyperlipidemia, were also found to be risk factors for Ischaemic heart disease (IHD) in haemophilia.

Differences in the prevalence of cardiovascular risk factors cannot explain this finding. Five studies investigated the association between risk factors and the development of atherosclerotic cardiac disease in hemophilia and all concluded that these are present to the same degree as in non-hemophilic individuals and cannot be the explanation for the reduced mortality rate.^{3,9,10,11,12} The hypocoagulable state of hemophilia patients might have a protective effect on thrombus formation, which precipitates infarction. It remains unclear whether the deficiency of coagulation factor VIII or IX exerts a protective effect on the development of atherosclerosis. Despite the relative protection against cardiovascular events, the incidence of ischemic cardiovascular disease in hemophilia patients is increasing, because life expectancy of these patients now approaches that of the general population.¹³ There has to be an explanation for the reduced mortality if cardiovascular risk factors and rates of atheroma are the same in hemophiliacs and control individuals. A difference in atherosclerotic plaque stability is a possibility but this has not

been studied. A more attractive alternative is the limitation of thrombus size and thus vessel occlusion in hemophiliacs once an atherosclerotic plaque has ruptured. Thrombus size and structure depend on thrombin generation, which in turn is critically dependent on the concentration of FVIII and FIX. Reduced thrombus generation is easily demonstrated by thrombography, thromboelastometry and thromboelastography as well as in flow chamber and animal studies.¹⁴ The age of the hemophilic population is increasing and even with the reduced rate, non-fatal cardiovascular events are likely to increase. There is little published evidence on the management of these events when they occur and better understanding of the situation is required.¹⁵ The delicate equilibrium between bleeding and thrombosis must be taken into account when treating these patients with antithrombotic medication or during cardiac intervention. It is important that cardiologists and haematologists are informed to optimize the multidisciplinary approach for these complex patients. In 1957, typical angina pectoris and extensive atherosclerosis were described for the first time in a patient with moderate haemophilia.¹⁶ Sramek *et al.* used B-mode ultrasound to quantify intima-media thickness (IMT), assessing early atherosclerotic changes in carotid and femoral arteries in 76 patients with bleeding disorders (59 hemophilia patients and 17 patients with von Willebrand disease) and in 142 healthy controls. No differences in IMT of the carotid artery were detected between patients with bleeding disorders and healthy controls. IMT of the femoral artery was minimally, but nonsignificantly, reduced in patients with bleeding disorders as compared to healthy controls (adjusted difference) 0.078 mm; 95% CI) 0.17 to 0.018 mm). Subgroup analysis revealed that femoral artery walls were thinnest in individuals with moderate to severe hemophilia (adjusted difference) 0.10 mm; 95% CI) 0.27 to 0.061 mm). From this study, it appears that the hypocoagulability caused by hemophilia has no, or at most a minor, effect on atherogenesis.¹⁷ Endothelial dysfunction precedes structural atherosclerotic changes in the vascular wall. Sartori *et al.* evaluated endothelial function by measuring flow-mediated dilatation and tissue-type plasminogen activator (t-PA) release before and after 20 min of brachial venous occlusion. Flow-mediated dilatation and the mean t-PA release were significantly lower, and thus impaired, in hemophilia patients as compared to control subjects.¹⁸ The lower cardiovascular mortality rates in patients with hemophilia are not solely the result of reduced atherogenesis. Although partial protection against atherosclerosis may exist in the hemophilia population, and might be dependent on the severity of hemophilia and the intensity of lifetime treatment with clotting factor concentrates, atherosclerosis does develop and is associated with standard cardiovascular risk factors.

The optimal overall management of patients with hemophilia is complex and requires the provision of preventive care, the use of replacement therapy with coagulation factors during acute bleeding episodes as well as for prophylaxis, and the treatment of the complications of the disease and the complications of anti-hemophilic therapy. The optimal management of cardiac complications will be an increasing challenge to clinicians caring for patients with hemophilia, as the treatment (eg, use of antiplatelet agents, anticoagulants) is expected to interfere with

hemostasis and require more intensive replacement therapy. There are no evidence-based guidelines for the treatment of ischemic cardiovascular disease in hemophilia patients. Atherosclerosis and ischemic cardiovascular disease require treatment to decrease the risk of thrombus formation. However, anticoagulant and antiplatelet medications increase the bleeding risk in hemophilia patients, and cardiovascular interventions are frequently complicated by bleeding. To minimize these risks, the clotting factor deficiency has to be corrected. However, infusion of clotting factor concentrates can be followed by ischemic cardiovascular disease.^{19,20} The equilibrium between bleeding and thrombosis must be taken into account when treating ischemic cardiovascular disease in hemophilia patients.

Before percutaneous coronary intervention, Pier M. Mannucci *et al* recommend bolus infusion of 80 U/kg Factor IX, followed by 30 U/kg Factor IX after 12 h. For secondary antithrombotic prophylaxis in patients who recovered from an acute coronary syndrome, they recommend low-dose aspirin (100 mg).²¹ Sufficient data does not exist to make hemophilia-specific recommendations for cardiovascular management. However, there is a clear need for cardiovascular risk screening in these patients, along with appropriate blood pressure control, cholesterol management, and smoking cessation programs as hemophilia patients age and develop these age-related comorbidities. In a similar article titled "Successful percutaneous coronary intervention for acute coronary syndrome in a patient with haemophilia B" published in 2015 by Koklu E *et al.*, a 41 year male was treated for Non ST-elevation myocardial infarction.²² The patient was administered dual antiplatelet therapy with loading doses of Aspirin and clopidogrel and underwent bare metal stent implantation 18 h after the onset of chest pain. The Authors present here a 52-year male with chest pain of one hour duration and Acute ST-elevation myocardial infarction with a history of oral bleeding the previous day. Patient had to undergo emergency primary percutaneous cardiac intervention from the left radial artery as there was hemophilic arthropathy of right elbow restricting movement. A delicate equilibrium between bleeding and thrombosis needed to be achieved during cardiac intervention. A history of oral bleed the previous day presented a dilemma to use of antiplatelet and anticoagulation medications during cardiac intervention. Absence of haemophilia-specific guidelines made decisions difficult. Patient underwent cardiac intervention under cover of single antiplatelet agent Tab Aspirin. Coronary angiogram was carried out from the left radial route as patient had restriction of movement of right elbow due to haemophilic arthropathy. As the coronary angiographic outcome was satisfactory, no coronary stent was placed. Placement of a coronary stent would have invited treatment with dual antiplatelet therapy for at least one year to prevent stent thrombosis as per standard of care management. But, this would have put the patient at increased risk of major bleed with underlying severe hemophilia B, and hence it was decided to administer one antiplatelet agent. Acute coronary syndromes and myocardial revascularization should be managed by a team that includes a cardiologist and a hemophilia expert.

REFERENCES

- Larsson SA. Life expectancy of Swedish haemophiliacs. *Br J Haematol*. 1985;59(4):593-602.
- Darby SC, Kan SW, Spooner RJ, Giangrande PL, Hill FG, Hay CR. Mortality rates, life expectancy, and causes of death in people with hemophilia A or B in the United Kingdom who were not infected with HIV. *Blood*. 2007;110(3):815-25.
- Kulkarni R, Soucie JM, Evatt BL. The Hemophilia Surveillance System Project Investigators. Prevalence and risk factors for heart disease among males with hemophilia. *Am J Hematol*. 2005;79(1):36-42.
- Ragni M, Belle SH, Jaffe R, Duerstein SL, Bass DC, McMillan CW. AIDS associated non-Hodgkin s lymphomas and other malignancies in patients with hemophilia. *Blood*. 1993;81(7):1889-97.
- Triemstra M, Rosendaal F, Smit C, van der Ploeg HM, Brie't E. Mortality in patients with hemophilia: changes in a Dutch population from 1986 to 1992 and 1973 to 1986. *Ann Intern Med*. 1995;123(11):823-7.
- Plug I, van der Bom JG, Peters M, Mauser-Bunschoten EP, De Goede-Bolder A, Heijnen L, *et al.* Mortality and causes of death in patients with hemophilia, 1992-2001: a prospective cohort study. *Thromb Haemost*. 2006;4(3):510-6.

7. Hirsh J, Guyatt G, Albers GW, Harrington R, Schunemann HJ. Antithrombotic and thrombolytic therapy: American College of Chest Physicians Evidence-Based Clinical Practice Guidelines (8th ed). Chest. 2008;133(suppl 6):110S-2S.
8. Sramek A, Kriek M, Rosendaal FR. Decreased mortality of ischaemic heart disease among carriers of haemophilia. Lancet. 2003;362(9381):351-4.
9. Ragni MV, Moore CG. Atherosclerotic heart disease: prevalence and risk factors in hospitalized men with haemophilia A. Haemophilia. 2011;17(6):867-71.
10. Rosendaal FR, Briet E, Stibbe J, van Herpen G, Leuven JA, Hofman A, *et al.* Haemophilia protects against ischaemic heart disease: a study of risk factors. Br J Haematol. 1990;75(4):525-30.
11. Miesbach W, Alesci S, Krekeler S, Seifried E. Comorbidities and bleeding pattern in elderly haemophilia A patients. Haemophilia. 2009;15(4):894-9.
12. Biere-Rafi S, Baarslag MA, Peters M, Kruip MJ, Kraaijenhagen RA, Den Heijer M, *et al.* Cardiovascular risk assessment in haemophilia patients. Thromb Haemost. 2011;105(2):274-8.
13. Tuinenburg A, Mauser-Bunschoten EP, Verhaar MC, Biesma DH, Schutgens REG. Cardiovascular disease in patients with hemophilia: Cardiovascular disease in patients with hemophilia. J Thromb Haemost. 2009;7(2):247-54.
14. Van Veen JJ, Gatt A, Makris M. Thrombin generation testing in routine clinical practice: are we there yet?. Br J Haematol. 2008;142(6):889-903.
15. Makris M, van Veen JJ. Reduced cardiovascular mortality in hemophilia despite normal atherosclerotic load. J Thromb Haemost. 2012;10(1):20-2.
16. Stewart JW, Acheson ED. Atherosclerosis in a haemophiliac. Lancet 1957; i: 1121-2.
17. Sramek A, Reiber JH, Gerrits WB, Rosendaal FR. Decreased coagulability has no clinically relevant effect on atherogenesis: observations in individuals with a hereditary bleeding tendency. Circulation. 2001;104(7):762-7.
18. Sartori MT, Bilora F, Zanon E, Varvarikis C, Saggiorato G, Campagnolo E, *et al.* Endothelial dysfunction in haemophilia patients. Haemophilia. 2008;14(5):1055-62.
19. Girolami A, Randi ML, Ruzzon E, Zanon E, Girolami B. Myocardial infarction, other arterial thrombosis and invasive coronary procedures, in haemophilia B: a critical evaluation of reported cases. J Thromb Thrombolysis. 2005;20(1):43-6.
20. Girolami A, Ruzzon E, Fabris F, Varvarikis C, Sartori R, Girolami B. Myocardial infarction and other arterial occlusions in hemophilia A patients. A cardiological evaluation of all 42 cases reported in the literature. Acta Haematol. 2006;116(2):120-5.
21. Mannucci PM, Roger EGS, Elena S, Mauser-Bunschoten EP. How I treat age-related morbidities in elderly persons with haemophilia. Blood. 2009;114(26):5256-63.
22. Köklü E, Bayar N, Yüksel İÖ, Esin M, Arslan Ş. Successful percutaneous coronary intervention for acute coronary syndrome in a patient with haemophilia B. Türk Kardiyol Dern Arş-Arch Türk Soc Cardiol. 2015;43(4):385-8.