

Pacemaker Twiddler's syndrome: Review Through a Case Report

Pande Arindam^{1*}, Sarkar Achyut², Ahmed Imran³, Chandra Naveen Ganiga Sanjeeva⁴ and Chakraborty Rabin¹

¹Department of Cardiology, Apollo Gleneagles Hospital, Kolkata, India.

²Department of Cardiology, IPGME & R and SSKM Hospital, Kolkata, India.

³Department of Cardiology, Medical College and Hospital, Kolkata, India.

⁴Department of Cardiology, Kasturba Medical College, Manipal, Karnataka, India.

ABSTRACT

Twiddler's syndrome, a rare but hazardous complication of cardiac pacemaker treatment, characterized by device malfunction due to dislodgement of cardiac leads resulting from some form of manipulation by the patient. In this report we present a case of pacemaker Twiddler's syndrome in a middle aged lady who presented with recurrent syncope after 1 month of initial implantation. Our patient was unique as she had almost none of the standard risk factors for this condition. In our case, reanchoring the lead as well as the pulse generator to the pectoral muscle with multiple anchoring sleeves prevented further recurrence.

Key words: Complication, Muscle twitching, Pacemaker, Risk factors, Syncope, Twiddler's syndrome.

INTRODUCTION

Twiddler's syndrome is a rare but potentially lethal complication of cardiac pacemaker treatment. It is characterized by device malfunction due to painless dislodgement of cardiac leads resulting from some form of manipulation by the patient. Here we are presenting a case of pacemaker Twiddler's syndrome which was unique in few aspects.

CASE REPORT

A 51-years woman was admitted to our institution with intermittent symptomatic complete heart block. A VVI system was implanted in the right pre-pectoral area and ventricular bipolar passive fixation lead was placed via the right cephalic vein approach. It was a medium size device weighing 26 gram (Ventralite 940+, Shree Pacetronics,

Indore) and the pacemaker pocket appropriately matched with the device size. The 24 h post implantation chest X-ray showed satisfactory pacing lead positions and all the pacing parameters (pacing threshold, sensing and impedance) were satisfactory. Her 1st follow up visit after two weeks was uneventful with satisfactory wound healing. One month later the patient presented to the emergency department with history of two episodes of syncope. She also reported twitching of her right pectoral muscle.

ECG at emergency department revealed loss of capture of pacemaker spikes (Figure 1). Pacemaker interrogation showed complete loss of pacing and sensing of the ventricular lead. The patient didn't admit any manipulation of the pulse generator. Patient was admitted and transferred to the pacing lab. Fluoroscopy revealed coiling of the pacing lead around the pulse generator (Figure 2). The pacemaker pocket was reopened. Fortunately, both the insulation and the conductor of the lead were intact. The same lead was repositioned and proved to be functional with good pacing and sensing parameters (Figure 3). The pulse generator was fixed on the pectoral muscle with non-absorbable sutures. No further complications were detected in one year follow-up.

*Corresponding address:

Dr. Arindam Pande

Department of Cardiology, Flat U 302, Binayak Enclave,
59 Kali Charan Ghosh Road, Kolkata,
Pin-700050, West Bengal, India.
E-mail: drapande@gmail.com

DOI: 10.5530/jcdr.2015.3.7

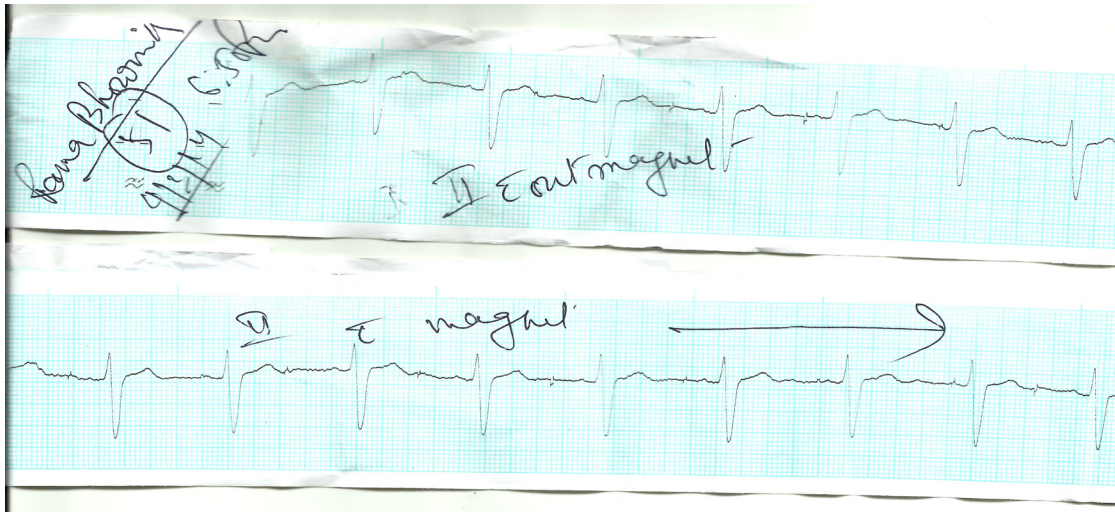
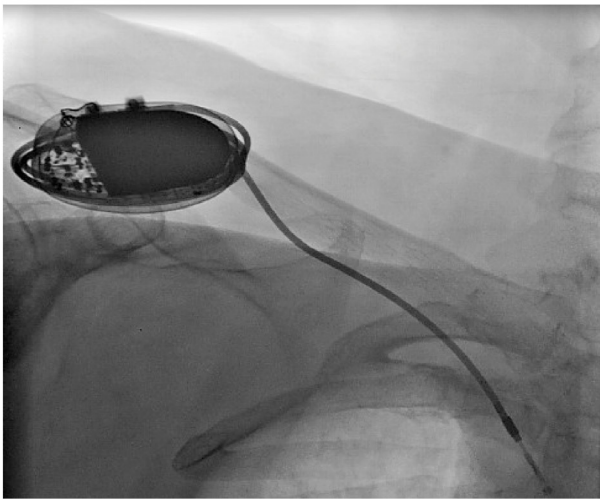
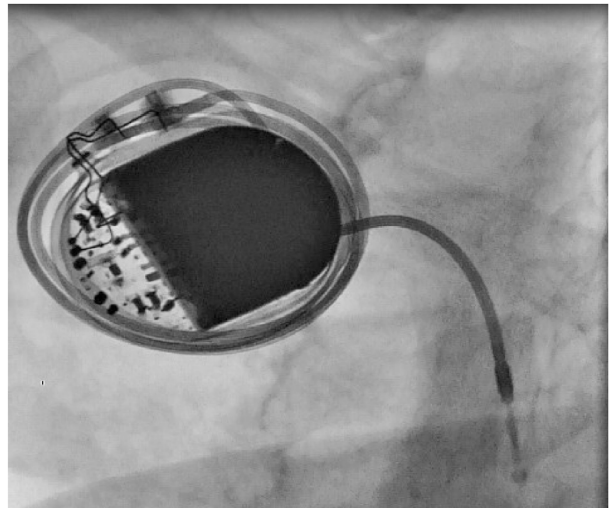


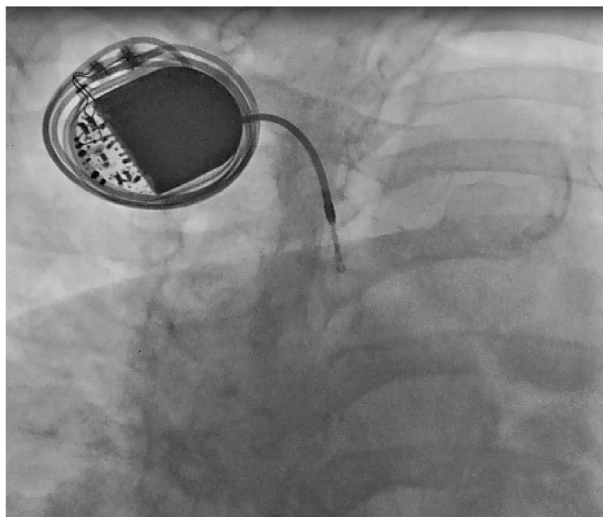
Figure 1: ECG showing loss of capture of pacemaker spikes



2 A



2 B



2 C

Figure 2(a, b and c): Detail from a fluoroscopy showing the coiling of the pacing lead around the pulse generator of a pacemaker in a 51-year-old woman

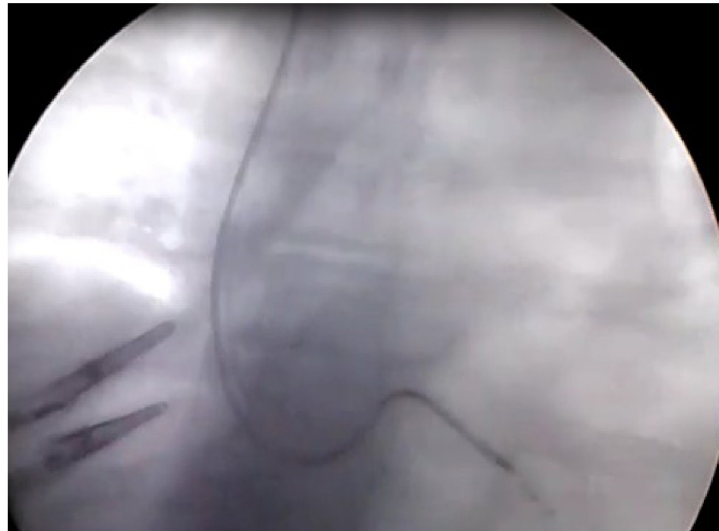


Figure 3: Final fluoroscopic image after repositioning of pacemaker lead

DISCUSSION

Bayliss *et al* were the first to describe Twiddler's syndrome.¹ The authors in that paper presented the main characteristics of Twiddler's syndrome-namely, the twisting or coiling of the lead around the pacing device, followed by lead retraction or lead fracture. They also noted that loss of capture and sensing are typically seen. Lead retraction is frequently associated with extra cardiac pacing. As the tip of the lead is pulled back toward the pocket, according to its position may produce failure to pace, diaphragmatic contraction by phrenic nerve stimulation, vagus nerve, pectoral muscle, or brachial plexus stimulation resulting in rhythmic arm twitching and finally may wrap around the pulsegenerator as in our case.² Older literature suggests a subgroup of partial Twiddler's syndrome where capturing function is maintained.³

Bayliss reported this "twiddling" in a patient with a thoracic, subcutaneous, transvenous pacing device.¹ The phenomenon has subsequently been described in implantable cardioverter defibrillator (ICD) patients⁴ with abdominal implants and endocardial (transvenous) ICD leads as well as those with thoracic devices and transvenous leads.⁵ Twiddler's syndrome has also been described with chemotherapy infusion devices⁶ and deep brain stimulators.⁷ Several patients twiddled multiple times.

Risk factors for this condition include elderly age group, obesity, female gender, psychiatric illness, and the small size of the implanted device relative to its pocket.⁸⁻¹⁰ Although the majority of cases occur during the first year of implantation, a "late Twiddler's syndrome" has also

been reported.¹¹ There are also case reports of Twiddler's syndrome within 48 hours of implantation.^{8,12} The majority, like our patient, deny any history of manipulation of the device.² The presence of heavy dressing also probably preclude the patients from any manipulation in early post operative period, so other factors such as movement of the body may have some role in this peculiar syndrome.¹²

The best approach to Twiddler's syndrome is prevention. Careful matching of the size of the device pocket to the implanted device is essential for patient comfort as well as to limit the available room in the pocket for pulsegenerator rotation. In addition, carefully anchoring the transvenous lead to the pectoral muscle is essential. Though, there was no difference in the frequency of twiddling seen whether or not a device suture was used to anchor the pulse generator to the pectoral fascia. It is reasonable to consider submuscular device implantation in patients with loose subcutaneous tissue, such as elderly, obese females. When Twiddler's syndrome has been confirmed, the leads are typically reanchored to the pectoral muscle with multiple anchoring sleeves. In addition, the device is often aggressively anchored to the pectoral muscle as well. Woven Dacron pouches have been available for many years and have been shown to efficaciously prevent device migration and flipping.¹³ Antibacterial envelopes are typically used in patients at high risk of device infection at the time of ICD implantation or generator change. Many authors advocate use of these envelopes for improving device stability in the pocket by reducing device migration and rotation. Active fixations of leads are also encouraged. Despite these interventions, repeat lead dislodgement is a serious clinical

issue. In our case the lead as well as the pulse generator was reanchored to the pectoral muscle with multiple anchoring sleeves. But truly speaking we also don't know what exactly prevented her further recurrence in one year follow up.

CONCLUSION

While twiddling is certainly uncommon (incidence of 0.07–1.1% in published reports^{8,14}) it remains a significant clinical problem, as damage to or dislodgement of leads will result in loss of pacing with possible injury or death in pacing-dependant patients. Furthermore, in ICD patients, particularly in whom the device was placed for primary prevention, dislodgement of the ICD lead is frequently asymptomatic as

these patients nearly always have the ICD programmed to minimize ventricular pacing. As a result, the only symptom in such patients may be failure to detect or treat potentially lethal ventricular arrhythmias. Our patient was unique in the sense that she had none of the standard risk factors for this condition except being a woman. Many aspects of this peculiar syndrome are still enigmatic and yet to be understood.

ABBREVIATION

| | |
|------------|--|
| ECG | : Electro Cardiogram |
| PPI | : Permanent Pacemaker Implantation |
| ICD | : Implantable cardioverter defibrillator |
| VVI | : Ventricle paced Ventricle sensed Inhibitory response |

REFERENCES

1. Bayliss CE, Beanlands DS, Baird RJ. The pacemaker-twiddler's syndrome: a new complication of implantable transvenous pacemakers. *Can Med Assoc J.* 1968; 99(8): 371-3.
2. Nicholson WJ, Tuohy KA, Tilkemeier P. Twiddler's syndrome. *N Engl J Med.* 2003; 348(17): 1726-7.
3. Dittrich J, Gartner U, Frese JH, Ran J, Rentsch I, Spaan G. Pacemaker Twiddler's syndrome. *Med Klin.* 1979; 74(1): 1755-60.
4. Boyle NG, Anselme F, Monahan KM, *et al.* Twiddler's syndrome variants in ICD patients. *Pacing Clin Electrophysiol.* 1998; 21(12): 2685-7.
5. Higgins SL, Suh BD, Stein JB, *et al.* Recurrent Twiddler's syndrome in a nonthoracotomy ICD system despite a Dacron pouch. *Pacing Clin Electrophysiol.* 1998; 21(1): 130-3.
6. Rodan BA, Martyak SN. Twiddler's syndrome: another twist. *South Med J.* 1988; 81(3): 418-9.
7. Penn DL, Wu C, Skidmore C, *et al.* Twiddler's syndrome in a patient with epilepsy treated with deep brain stimulation. *Epilepsia.* 2012; 53(7): e119-21.
8. Fahraeus T, Höjler CJ. Early pacemaker twiddler syndrome. *EP.* 2003; 5(3): 279-81.
9. Gupta R, Lin E. Twiddler syndrome. *J Emerg Med.* 2004; 26(1): 119-20.
10. Castilo R, Cavusoglu E. Twiddler's syndrome: An interesting cause of pacemaker failure. *Cardiology* 2006; 105(2): 119-21.
11. Dursun I, Yesildag O, Soylu K, Yilmaz O, Yasar E, Meric M. Late pacemaker Twiddler syndrome. *Clin Res Cardiol.* 2006; 95(10): 547-9.
12. Mandal S, Pande A, Kahali D. A rare case of very early pacemaker Twiddler's syndrome. *Heart Views.* 2012; 13(3): 114-5.
13. Shandling AH, Ellestad MH, Castellanet MJ, Messenger JC. Dacron-woven pacemaker pouch. Influence on long-term pacemaker mobility. *Chest* 1991; 99(3): 660-2.
14. Hill PE. Complications of permanent transvenous cardiac pacing: a 14-year review of all transvenous pacemakers inserted at one community hospital. *Pacing Clin Electrophysiol.* 1987; 10(3 Pt 1): 564-70.