

Histological Aspect Of Left Atrial Appendage (Laa) With Special Stains Pas (Periodic Acid Schiff) & Vangeison's

Dr. Garima Pardhi ¹, Dr. Jaya Deshmukh ², Dr. Rajveer Singh Chourasia³, Dr. Manish Patil ⁴

¹Demonstrator in Department of Anatomy, (A.B.V.G.M.C.) Atal Behari Vajpayee Government Medical College, Vidisha (M.P.), sky1135@gmail.com

²Demonstrator, in Department of Anatomy, Gandhi Medical College, Bhopal(M.P.), drjayadeshmukh1@gmail.com

³Professor & HOD, Department of Anatomy, Government Medical College - Singrauli (M.P.),

rajveer.chourasia79@gmail.com ⁴Professor & HOD, Department of Anatomy, R. D. Gardi Medial College & Hospital Ujjain (M.P.), manishpatil60@yahoo.com

Corresponding Author:

Dr Jaya Deshmukh, Demonstrator, Anatomy Gandhi Medical College Bhopal (M.P.) drjayadeshmukh1@gmail.com

Affiliation URL:

<https://kims.kiit.ac.in/>

Abstract:

Background: It is axiomatic that an understanding of the complex architecture of the atrial musculature should improve understanding of its activation and contraction. The left atrium possess a venous component, a vestibule and an appendage and shares the septum. The structure of the heart undergoes constant adaptation to physiologic changes in the organism. LAA is a major endocrine organ and is the main producer of ANP (atrial natriuretic peptide) in the human heart. Atrial cardiocytes of the mammalian heart contain granules which are morphologically similar to those in peptide secreting endocrine cells. The cardiocytes of LAA contain the greatest density of ANF granules found in Left Atrium and it is therefore of interest to carry out further studies on these granules.³

AIMS: Looking to the great clinical significance that is given to the morphology of LAA & its predilection as a site for thrombus formation, we've conducted a detailed study histologically of LAA. To investigate LAA and study the arrangement of muscle bundles collagen fibres & connective tissue of LAA histologically (with special stains -) and the see findings were co-related with that described in the literature.

Material & methods: The materials for the present study were collected from the Department of Anatomy & Forensic medicine of Sri Aurobindo Medical College and Post Graduate Institute, Indore. Randomly five hearts were selected and slides of LAA from different sites (apex, inferior margin and atrio-auricular junction) were prepared by routine Histological Technique and stained by Haematoxylin & eosin and special stains prepared)

CONCLUSION: This study of its histological features is an attempt to establish the cause of various pathologies related to arrhythmias.

Keywords: : LAA (Left atrial appendage), ANF (Atrial natriuretic factor), histologically, P.A.S, VAN GEISON'

INTRODUCTION

The left atrium possess a venous component , a vestibule and an appendage and shares the septum. The Left Atrial Appendage (LAA) is characteristically a small finger like extension in human hearts and has crenations overall lobes that are potential sites for disposition of thrombus.¹

For decades anatomy text books tended to focus on the ventricles because of their import antroleas pumping chambers.The two atria have long been looke datas collecting chambers, or even just conduits for blood to get through to the ventricles, hence attracted less interest for studying them.

The structure of the heart undergoes constant adaptation to physiologic changes in the organism. These changes are varied and take place from the time of embryonic development to senescence. The difference between physiological and pathological adaptive mechanisms is some time is subtle. Therefore, it is import an to understand that the structure of the heart is modified by a continue of involving adaptation of the organ to the needs of the organism. In many instances, pathologic changes affecting the heart have a structural substrate, whether they are due to genetic or acquired processes. Like any other organ, the heart has cells that contribute to the formation of the stroma (the connective tissue scaffold of the organ) and cells that form the parenchyma (the physiological-working-tissue of the organ, in the case of the heart these are the myocytes). The basic cellular unit of the parenchyma of the cardiac muscle is the cardiac myocyte.⁴ Actually, the LAA is are amount of the original embryonic left atrium formed during the third week of gestation. The LAA lies within the pericardium inclose contact with the free wall of the left ventricle. It is therefore likely that blood flow, in and out of the LAA, depends to a significant degree on a properly functioning left ventricle. The LAA empties into the left atrium through an orifice located between the left upper pulmonary vein and the left ventricle.⁵ The trabecular LAA is are mnant of the original embryonic left atrium that develops during the third week of gestation. The main smooth-walled left artrial cavity develops alter and is formed from an outgrowth of the pulmonary veins. The function of the LAA is unknown. In studies performed more than 50 years ago, it was speculated that the atrial appendages fill the space that is created with in the pericardial sac during ventricular systole as the ventricles eject blood and decrease in size. The appendages passively fill during ventricular systole and then passively empty during ventricular diastole.²

Atrial cardiocytes of the mammalian heart contain granules which are morphologically similar to those in peptide secreting endocrine cells. These secretory granules were discovered by Kisch (1956), a finding confirmed by several investigators (Posche, 1957; Bompiani et al., 1959). The granularity of the atria can be altered experimentally by salt and water loading order privation (DeBold,1979) and by procedures which cause perturbation of salt and water balance; these include adrenal regeneration hypertension (Martinez, 1966) and adrenalectomy. These granules are known as Atrial Natriuretic factor (ANF).⁶

LAA is a major endocrine organ and is in producer of ANP (atrialnatriuretic peptide) in the human heart. The ANP concentration is 40 times higher in the LAA walls than in the rest of the atrial free wall and in the ventricles. A study of patients having undergone the maze procedure

and associated LAA removal found a significantly lower ANP secretion and acumens curate increase in salt and water retention. Whether this could eventually lead to hypertension is not known.⁵ So, analysis of ANF has shown that LAA contain about 30% of all cardiac ANF. The cardio cytes of LAA contain the greatest density of ANF granules found in Left Atrium and it is therefore of interest to

carry out further studies on these granules.³

AIMS and OBJECTIVES

Looking to the great clinical significance that is given to the morphology of LAA & its predilection as a site for thrombus formation, we've conducted a detailed study histologically of LAA.

- To investigate LAA and study the arrangement of collagen bundles of LAA histologically (with a special stain-Van Geison's) and these findings were co-related with that described in the literature.

The specimenswerephotographedand photomicrography of appropriate histological sections was carried out.

- These findings were correlated with those cited in the literature. An attempt was made to draw a correlation of these findings with the functions of LAA.

- Theseinturnhelpinunderstandingonitsclinicalsignificance andwouldbeofhelp to manage these patients.

MATERIALS&METHODS -

The materials for the present study were collected from the Department of Anatomy & Forensic medicine of Sri Aurobindo Medical College and Post Graduate Institute, Indore. Randomly five hearts were selected for histological purposes of Left Atrial Appendage (LAA) which included the following:

For histology: slides ofLAA from different sites (apex, inferior margin and atrio-auricular junction) were prepared by routine Histological Techniques and stained. II.HISTOLOGY:

Small pieces (2.0cm X 0.5cm) of LAA were taken from different sites (apex, inferior margin and atrio-auricular junction).The tissues were fixed in 10% formalin, and were processed for routine histological procedures – like dehydration, clearing and after wax embedding, blocks were prepared. Sections 5-6micron thick were cut andstained with the following stains: ^{7,8}

H & E: Method for staining are-

1. Sections were de waxed with xylene and the sections were taken to water (with descending grades of alcohol).
2. Staininhaematoxylin,inajarfor5-10minutes.
3. Washwellinrunningtapwaterfor2-3mnutes.
4. Remove excess stain by decolorizing (differentiating) in 0.5-1% hydrochloric acid in 70% alcohol for few seconds.
5. Washinalkalinerunning tapwaterfor5minutes.
6. Stainin1%aqueouseosinfor1minutes.
7. Wash surplus stain in water.

8. Dehydrate in alcohol, clear in xylene. Mount in D.P.X. or Canada balsam.

ii) P.A.S.: Method for staining are-

1. Bring sections through xylene and graded alcohols up to water.
2. Place for 5 minutes in 0.5% aqueous periodic acid.
3. Rinse in tap water.
4. Rinse in distilled water.
5. Place in Schiff's reagent for 15 minutes.
6. Place in running tap water briefly.
7. Counter stain with haematoxylin.
8. Dehydrate in ascending strengths of alcohol.
9. Clear in xylene.
10. Mount in D.P.X.

11. **Van Geison:** Method for staining are

iii) Stain sections with any of the alum haematoxylin (generally

Harris haematoxylin is used).

- a. Wash thoroughly in tap water.
- b. Stain in the above Van Geison's solution for 3-5 minutes.
- c. Rinse in tap water and differentiate in 1% acetic alcohol.
- d. Dehydrate in absolute alcohol.
- e. Clear in xylene through 2 or 3 changes and apply coverslip with D.P.X.

Summary and conclusion

This study of its histological features is an attempt to establish the cause of various pathologies related to arrhythmias. The histological features of all the three regions of LAA studied conform to the classical description of all these layers of the atrial wall, with a few exceptions:

- i) Some special category of cells was seen within the connective tissue of the endocardium;
- ii) Sub-endocardial tissue showed stratification along with a number of elastic lamellae;
- iii) Thick cardiomyocytes showed the presence of in granules in the peri-nuclear zone;
- iv) At places the epicardium was lined by cuboidal to columnar cells.

The present findings will be of great help in the interpretation of Trans-Esophageal-Echocardiography (TEE) and the

understanding of the thrombo-embolic phenomenon.

OBSERVATIONS

The Left Atrial Appendage (LAA) is a very unique structure within the pericardial cavity, although small in size and having a variegated appearance, it is notorious for arrhythmias and thrombo-embolic phenomenon. This study was undertaken with the objective that certain features of histological anatomy may help in elucidating certain special features of LAA which can be correlated with its tendency for malfunctioning

HISTOLOGY

Histological features of the three regions (atrio-auricular junction, inferior margin and apex) studied showed almost identical features with only very slight variations that have been included in the observations described below. Due to the same reason, only selected photomicrographs (of special stain-PAS & Van Geison) have been included. Following are the microscopic findings:

Epicardium-

- The outer layer of the heart is termed epicardium. There was a thin layer of epicardium where deep to it greater amount of adipose tissue was present and the epicardium was thick if adipose tissue was scarce or absent. These features were seen in all the three sites studied namely atrio-auricular junction, inferior margin and apex.

- Lining cells of epicardium in (Atrio-Auricular Junction) AAJ showed the presence of flattened cells which at places were cuboidal to columnar, (fig.1) whereas at some places, in sections of apex and inferior margin lining of cuboidal cells was seen.

- Deep to the lining epithelium were layers of fibrous tissue intermixed with elastic fibers (fig.3). On a deeper plane variable amount of adipose tissue was present (fig.3). Similar findings were seen in sections taken from apex and inferior margin. In the sub-epicardial region many large blood vessels and nerves were present.

- At places in section taken from apex, in sub-epicardial region there was large amount of fat and it was covered by flattened cells.

- At places in sections taken from apex, in sub-epicardial region there was large amount of fat and it was covered by flattened cells.

B) Myocardium-Myocardium of AAJ in the auricular wall showed variable thickness. At the site of musculipectinati it was quite thick, elsewhere it was so thin that endocardium and epicardium were almost touching one another separated by very small amount of connective tissue(fig2.)

- Size of the fibers was variable. Fibers were oriented in different directions. There was presence of large number of blood vessels of various sizes and types seen between the muscle fibers. They were present in sections of all the three sites studied.

- Musculi pectinati were seen as projections in the auricular cavity being lined by endocardium. In musculipectinati there was presence of longitudinal and transverse fibers. Similar findings were observed in sections taken from apex and inferior margin.

- Myocytes with PAS positive sarcolemma was observed (fig), which was also, seen in sections taken from apex and inferior margin.

- Presence of granules, which were of deep purple color, were observed in peri-nuclear area in some of the muscle fibers. Similar findings were there in sections taken from apex and inferior margin.

b) Endocardium-

- The endocardium is the innermost layer that lines the chambers of the heart. Endocardium of AAJ was not uniform; it was wavy in character where it was thin. This was also, seen in sections taken from apex and inferior margin. Elastic fibers, which were non-cellular and eosinophilic, were seen. Well-defined zonation could be observed in sub-endothelial connective tissue, which showed wavy elastic fibers also (fig.). Elastic fibers were present along with variable amount of connective tissue. Thin short elastic fibers mixed with fibers of connective tissue were also observed in the deeper zones. These features were also seen in sections taken from apex and inferior margin. (fig 3.).

- Some special cells were present in the endocardium, below the endothelial lining. These cells were present in groups and at distances, were darkly eosinophilic cytoplasm with small and centrally placed nucleus. These cells were not seen through out the endocardium. Similar finding was seen in sections taken from apex and inferior margin.

- In addition, in the deeper part of the endocardium at places rounded empty looking cells were present. These were also found in sections taken from apex and inferior margin.

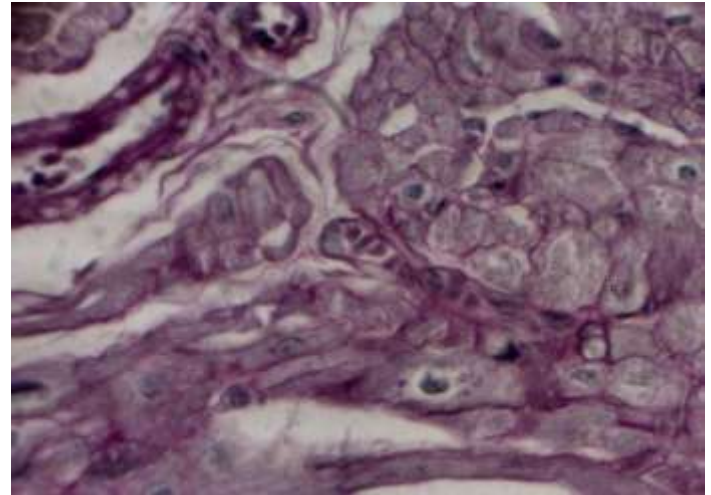
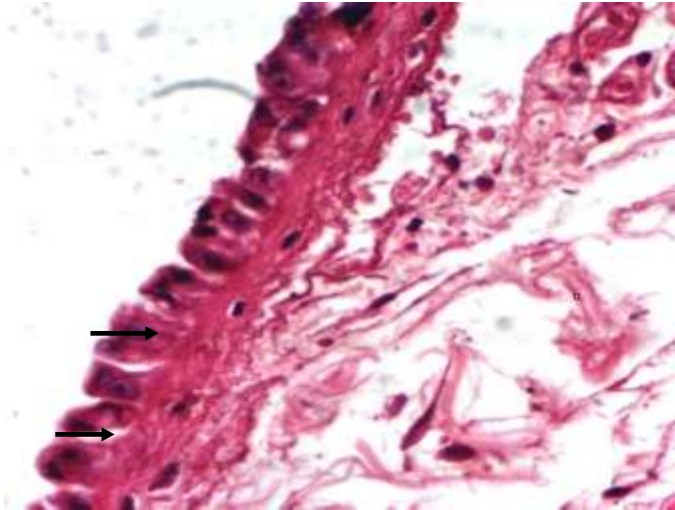
- The atrial wall endocardium was smooth with flattened endothelial cells. Whereas, auricular wall showed projections. Where amount of loose connective tissue increased in the deeper part of endocardium, there were a number of undulations seen in the endocardial lining. At places sub-

endocardial space with loose connective tissue was observed. (fig.) There was absence of sub-endocardial space in some regions, so that the endocardium was almost adherent to myocardium.

- In section taken from apex, at places,

musculipectinaticameclosesetoeachotherthereby separating part of the auricular cavity.

Fig. 3: Photograph showing connective tissue mixed with elastic fibers (black), endocardium., Sub-endocardial loose connective tissue (blue). (Van Gieson)



MYOCYTES WITH PAS POSITIVE SARCOLEMA

Fig.1: Photograph of section of Atrio-auricular junction showing cuboidal tall columnar cells, epicardium. (H & E)

ENDOCA

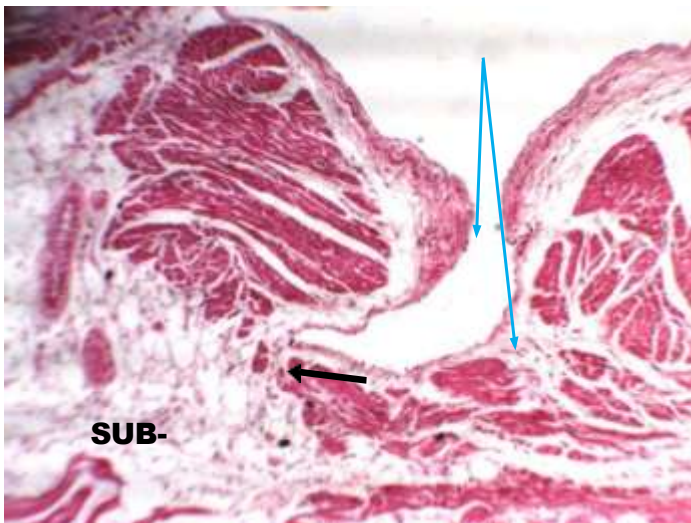

Fig.2: Photo showing sub-epicardial continuous with sub-endocardial tissue (black). Contrast between thick and thin endocardium (blue) (H & E)

References:

1. Wang K, Ho SY, Gibson DG, Anderson RH. Architecture of atrial musculature in Humans. *Br. Heart J* 1995; 73:559-565.
2. Bold AJ D, Raymond JJ, Bencosme SA. Atrial specific granule of the rat Heart Light Microscopic staining and Histochemical Reaction. *J of Histochemistry and Cytochemistry* 1978; 26:1094-1102.
3. Saady NMA, Obel OA, Camm AJ. Left Atrial Appendage: Structure, Function and role in thrombo - embolism. *Heart* 1999; 82:547-555.
4. Cardiac histology (I). heart. org. Cited on 02/08/2013; Available from URL: http://www.eheart.org/pages/01_cardiac_structure/01_Cardiac_Structure_Cardiac_Histology_001.htm.
5. Larsen HR. Left Atrial Appendage: Useless or Priceless? The Afib Report. Available from URL: <http://www.afibbers.org>.
6. Lindop GB M, Mallon EA, MacIntyre G. Atrial natriuretic peptide in the heart and pancreas. *Histology & Histopath* 1986. 1:147-154.
7. Carleton HM, Drury RAB. Histological technique for normal and pathological tissues and the identification of parasites. London Oxford University Press New York Toronto 3rd Edition 1957; 100-105.
8. Culling CFA. Handbook of Histopathological and Histochemical Techniques. Butter worths 3rd Edition 1975; 211-219

