

ORIGINAL ARTICLE

Assessment of Functional Outcome Following Mini Open Transosseus Rotator Cuff Repair for Complete Rotator Cuff Tears of the Shoulder

Haemanath Pandian^{1,2}, Preetinder Paul Singh¹

¹Consultant Orthopaedic Surgeon, Sayee Speciality Hospital, Padappai, Kancheepuram, Tamil Nadu.

²Consultant Orthopaedic Surgeon, Chettinad Academy of Research Education, OMR, Chennai, Tamil Nadu - 630103.

¹Consultant Orthopaedic Surgeon, Sayee Speciality Hospital, Padappai, Kancheepuram, Tamil Nadu.

Corresponding Author

Dr. Haemanath Pandian, MS, Consultant Orthopaedic Surgeon, Chettinad Academy of Research Education, OMR, Chennai-630103.

Email address: haemanath@gmail.com

Received: 5th June 2021; Accepted: 10th July 2021; Published: 19th August 2021

Abstract

Background: The mini-open surgical approach for rotator cuff repair is most appropriate for small to medium-sized tears encompassing one tendon tear of the supraspinatus or two tendon tears of the supraspinatus and the upper half of the infraspinatus. The purpose of this study was to assess the functional outcome of mini-open transosseous rotator cuff repair for complete rotator cuff tear of the shoulder.

Method: This prospective study was performed on 12 consecutive patients who presented with full-thickness rotator cuff tear involving 1-2 for full-thickness rotator cuff tear. All patients underwent transosseous mini-open cuff repair. The mean age, gender ratio, mean duration of follow-up, affected side of the shoulder, deOrto and Cofield classification of tear size, Goutallier's fatty infiltration were noted down for all patients. American Shoulder Elbow Society (ASES) and constant Murley functional score were calculated at 3rd month, 6th month and at 1 year follow up.

Results: A total of 12 patients whose mean age was 56.29 ± 4.11 The mean Constant-Murley and ASES scores significantly improved from 45.17 ± 7.31 and 80.75 ± 4.56 at 3 months to $87.67 \pm$

5.73 and 86.58 ± 4.81 at 1 year with a p-value of 0.0001 and 0.005 respectively for male and 56.00 ± 5.66 years were followed-up for 6 months. Tear size was graded according to deOrto and Cofield classification and massive tears were excluded, with the maximum of 6 patients having medium tears. Fatty infiltration was also assessed, 50% of patients had Goutallier's Stage 1 and 42% Stage 2.

Conclusion: The functional outcome after transosseous mini-open rotator cuff repair for complete rotator cuff tear was good to excellent as per Constant and Murley score and ASES score.

Keywords: Rotator cuff repair, mini-open surgical approach, complete rotator cuff, shoulder

Introduction

Rotator cuff disorders are the most common cause (up to 70%) of shoulder pain, with a lifetime prevalence approaching 70%. (1) Magnetic resonance imaging (MRI) studies have shown the prevalence to be 28% in subjects over 60 years, rising to 38% of over 70 years. (2) The incidence is expected to grow as the population ages and remains active.

Rotator cuff repair is one of the most common procedures performed in the shoulder with significant predictable pain relief and functional improvements in all age groups. (3) (Figure 1) The reasons to proceed with surgical treatment are dependent on the individual patient, the etiology of injury, the duration of symptoms, the impact on quality of life, and the failure of non-operative treatment. (4) The operative repair of a torn rotator cuff tendon can be accomplished through 1 of 3 surgical approaches: open, mini-open, and all-arthroscopic.

The mini-open approach has the benefits of less perioperative morbidity and a decreased risk of deltoid detachment, as the split in the deltoid is limited to the lateral deltoid. (5) The mini-open approach is most appropriate for small- to medium-sized tears encompassing a one-tendon tear of the supraspinatus, or possibly a two-tendon tear of the supraspinatus and the upper half of the infraspinatus. (6) These are not suited for tears with fixed humeral head elevation, significant chronic retraction of the tendon, or evidence of fatty infiltration and atrophy of the muscle belly. Transosseous suturing gives more biological fixation with greater contact and pressure distribution. (7) The purpose of this study was to assess the functional outcome of the cost-effective transosseous Mini open transosseous rotator cuff repair for complete rotator cuff tear of the shoulder.

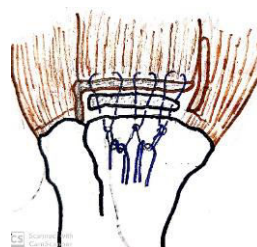


Figure 1: Transosseous cuff repair.

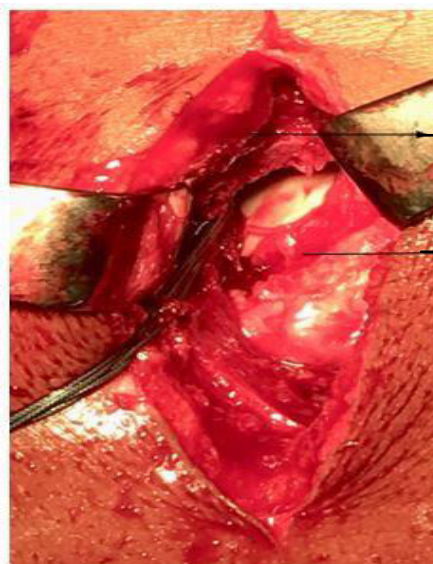Methods

We conducted a prospective observational study on the functional outcome of transosseous mini-open rotator cuff repair for complete rotator cuff tear, which was conducted in a rural tertiary care hospital with a follow up of 6 months. After approval by the Institute Ethics Committee, patients with complete rotator cuff tear either presenting for the first time or/and those who underwent transosseous mini-open rotator repair and were in the follow-up period during study duration were enrolled in the study by simple convenient sampling method after recording the clinical and MRI findings. The inclusion criteria were skeletally matured patients >18 years with complete rotator cuff tear due to both trauma and degeneration diagnosed by clinical examination and MRI findings were included. Rotator cuff tear ≤ 5 cm found at the time of surgery, with no radiographic signs of fracture of the glenoid or the greater or lesser tuberosity, and no episodes of shoulder instability. Massive rotator cuff tears >5cm or involving more than two tendons), partial rotator cuff tears, Goutallier's grade 4 fatty cuff atrophy as seen on MRI, patients with other associated injuries like fractures, labral tears, and patients who are unlikely to comply with physiotherapy protocol eg: patients with psychiatric illness were excluded from the study. Written informed consent for undergoing transosseous mini-open rotator cuff repair as well as enrolling for the study was obtained from the 12 patients, who fulfilled these criteria. A proper history and clinical examination were recorded and investigations in the form of basic blood workup, anteroposterior and lateral projections radiographs, and MRI of the affected shoulder were done immediately

Surgical Procedure

General Anaesthesia was used. The patient was positioned in either beach chair or lateral decubitus positions. The Beach chair position was preferred. Transosseous mini-open rotator cuff repair was done through a lateral approach; a 4-5 cm incision was made from the anterolateral edge of the inferior border of the acromion and raphe between the anterior

and middle deltoid was found and deltoid was split. (Figure 2) Subacromial bursa was identified and partial bursectomy did. The defect was identified and its size was measured. Release of the rotator cuff was done. The torn end of the tendon was mobilized. The end of the mobilized tendon was debrided to get the raw edge. (Figure 3) A trough was made using a burr at the greater tubercle insertion site using a burr. Transosseous tunnels were made distal to the trough. Using a No.2 ethibond (non-absorbable suture polyethylene tetraphthalate), sutures were first passed using the No.5 Mayo needle through the bone tunnel. The sutures were then passed through the tendon about 1cm from the edge and brought back in a box fashion. The suture is then passed through another transosseous tunnel and suture tied on the Greater tuberosity. (Figure 4) The repair is carried out from anterior to posterior. Usually, 2-3 sutures were required depending on the size of the tear. Through wash given. Skin and subcutaneous tissues closed in layers and sterile dressings were applied.



Tore cuff

Greater
tuberosity

Figure 2: Cuff tear

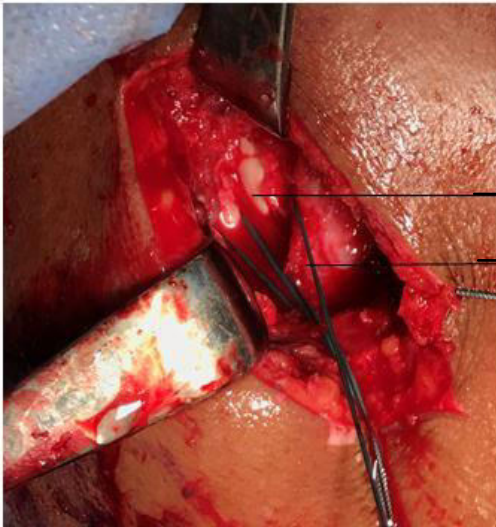


Figure 3: Retracted tendon being pulled

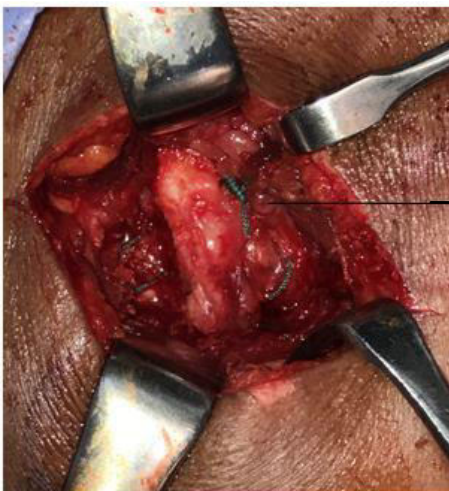

Figure 4: Cuff repair

Follow up

Postoperatively, strict physiotherapy protocols were followed based on the size of the tear, condition of the tissue, and stability of the repair. After the repair, a low-profile arm sling was worn for 6 weeks. At 2 weeks passive assisted exercises, pendulum exercises were started to avoid stiffness, disuse atrophy. Active full range of motion was permitted after 6 weeks followed by strengthening exercises. Patients were cautioned that overaggressive

use of the extremity before 6 months can lead to disruption of the repair. At each follow-up, patients were assessed clinically for pain relief, stability, range of motion, and activities of daily living. Functional assessment was done using the Constant-Murley American Shoulder Elbow Society (ASES) score at the 3rd month, 6th month, and 1-year postoperatively. Complications if any were noted.

Statistical Analysis

All data were entered into a data collection proforma sheet and were

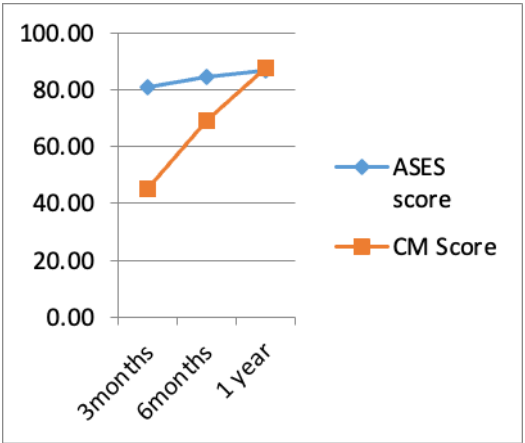
entered into Excel (MS Excel 2011). The sheet had a visual map for marking and was divided into indications for both genders. The data was entered and analyzed using the Statistical Package for Social Sciences (SPSS) for Windows 26.0. (SPSS, Inc. Chicago, Illinois) Confidence intervals were set at 95%, and a p-value \leq of 0.05 was considered statistically significant. Data were presented as mean and standard deviation for continuable variables and in frequency for categorical variables. An independent sample t-test was used to find the difference in age between genders. The paired sample t-test was used to find the difference between ASES, Constant and Murley at 3 months 6 months, and 1 year. The difference in 3 months, 6 months, and the 1-year score of ASES, Constant and Murley score between

genders were found using an independent sample t-test. The 6th-month outcome of the patients was presented as frequency.

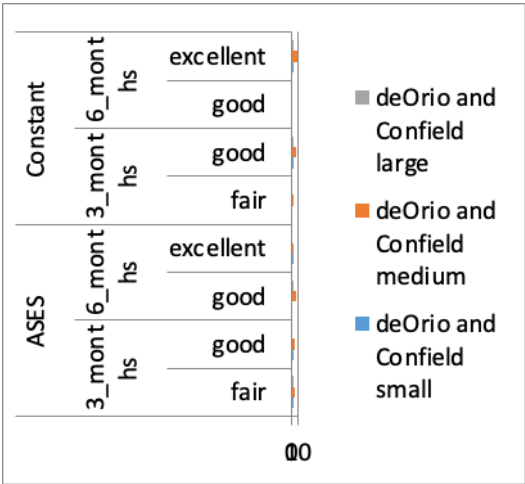
Results

Of the 12 consecutive patients (7 men and 5 women) included in study 9 right-sided and 3 left-sided symptomatic complete rotator cuff tear was identified with a mean age of 56.16 years. The tear size was classified by deOrío and Confíeld classification and was found to be 9 medium, 2 small, and 1 large size tear. Fatty degeneration was classified by Goutallier’s classification and we found 6 patients were stage I, 5 patients were stage II, and 1 patient was stage III. No patients were lost to follow-up.

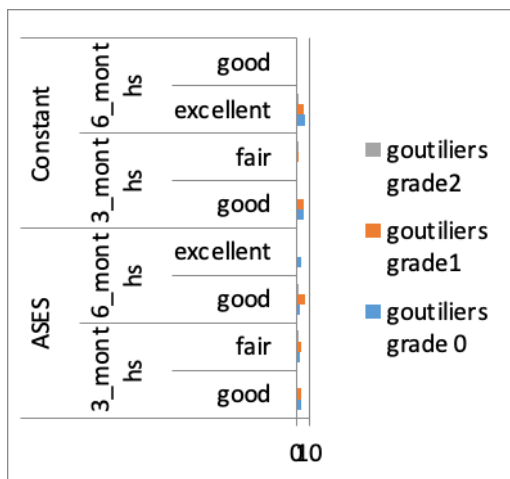
The mean 3 months post-operative ASES and Constant-Murley scores in patients with rotator cuff tears were 80.75 ± 4.56 and 45.17 ± 7.31 . which improved to 86.58 ± 4 and 87.67 ± 5.73 by the end of 6 months, showing a significant p-value of 0.005 and 0.0001 respectively. No significant difference in the functional scores was observed between males and females. The improvement in ASES score and Constant score at 3month, 6months, and 1 year. (Graph 1) The tear size was correlated with the ASES score and Constant Murley score, results showed a better functional outcome with smaller tears. (Graph 2). Fatty degeneration classified using gautiliers classification, in correlation with functional scores show better results in grade 0 and grade 1 tears. (Graph 3)



Graph 1: ASES and Constant scores at 3months, 6 months, and 1 year.



Graph 2: Correlation of tear size to the functional scores.



Graph 3: Correlation of Goutallier's fatty degeneration to functional scores.

Discussion

The study on the functional outcome of transosseous mini-open rotator cuff repair for complete rotator cuff tear using ASES and Constant and Murley scores showed good to excellent results by the end of 1 year with better results in small and medium-sized tears. As Goutallier's fatty degeneration increases the outcome following repair was average. In our study group, most of the patients were between 50-60 years. Boehm et al and Robinson P et al (8) studied the outcome of rotator cuff repair in the elderly and concluded that the results in both the younger age group and patients above 70 years were equivocal. The systematic review by Khair MM et al (9) on 11 studies reporting on a total of 925

shoulders between January 1966 and March 2015 stated with the increase in Goutallier's fatty infiltration there was a decrease in the functional outcome. Even Ohzono H et al.(10) in his study in large and massive tears concluded the same. However, all the patients in our study had excellent functional outcomes by the end of 1 year. This might be because we exclude patients with fatty infiltration of grade 4 or above.

In 1990, Levy HJ et al.(11) reported the patients with small or medium tears all had satisfactory outcomes. Whereas Blevins FT et al(12) and Baysal D et al.(13) reported no correlation between cuff tear size and functional outcomes. In our study, we had 9 patients with medium and 2 patients with small tears, they showed good to excellent results on both ASES and Constant and Murley scores. Cho CH et al.(14) assessed 128 patients who underwent anterolateral approach for the mini-open rotator cuff repair and found that 47 (87.0%) of 54 patients with large or massive tears had satisfactory clinical outcomes. In our study, massive rotator cuff tears were excluded however, one patient with a large tear showed fair and good results at 3 months and 6 months respectively. Even Paulos LE and Kody MH.(15) recommended mini-open repairs for patients with tears retracted less than 2 cm regardless of tear size after his review on mini-open repairs in 18 patients with an average follow-up of 46 months showed excellent results in 16 patients.

Sauerbrey AM et al.(16) in their study of 37 patients reported good to excellent functional outcomes after mini-open rotator cuff repair, with improvement in the ASES score from 52 to 89 by the end of 1 year on an average. Similarly, Baysal D et al.(17) prospectively reviewed 84 patients who underwent mini-open repair and reported a statistically significant improvement in ASES to score from 53.3 preoperatively to 90.6 1 year postoperatively and improved range of motion. Whereas in our study we did not record the pre-operative score, however, the ASES score improved from 80.75 to 86.58 between 3 weeks and 6 weeks. Your T et al.(18) compared outcomes of all-arthroscopic repair versus mini-open repair in a series of 84 patients who underwent repair of small, medium, or large tears. There were 42 arthroscopic repairs and mini-open repairs. The ASES scores averaged 91.1 for the arthroscopic group and 90.2 for the mini-open group. In our study, the average ASES score was 86.58 with 9 good and 3 excellent results.

B.C. Hanusch, L. Goodchild, and A. Rangan(19) in their study of 24 patients were included which were assessed prospectively before and at a mean of 27 months after mini-open repair using constant and Murley scoring system. The mean Constant and Murley score improved significantly from 36 before to 68 after surgery which was statistically significant. Whereas in our study the mean Constant and Murley score at the end of 3 months was 45.17 ± 7.31 which improved to

87.67 ± 5.73 at 6 months itself which is also significant with a p-value < 0.0001 . A study done by Sharma V et al.(20) examined 34 patients with mini-open rotator cuff repair, the Constant and Murley score revealed poor outcomes among all the patients during 3 weeks follow up while at 6 weeks follow up all the patients had fair function suggesting marginal improvement in function. At 3 months follow up all the patients had a good outcome, whereas in our study 2 patients had fair outcome and 10 patients had good outcome by the end of 3 months and at last follow up that is, 6 months all the patients had a constant score of < 11 suggestive of the excellent functional outcome as in correspondence with our study. Constant scores from enrolment to six months follow-up also was statistically highly significant. The study concluded that mini-open repair of rotator cuff repair for rotator cuff injuries offers excellent functional outcomes at long-term follow-up as correlating with our study. Angst, F et al.(21) in his study on Measures of adult shoulder function said ASES is comparable to the Shoulder Pain and Disability Index (SPADI) and the Constant Murley Score in terms of responsiveness and long term functional outcome. (22) However, In our study Constant and Murley score gives significant improvement from 3rd month to 6th month were the functional improvement according to ASES is less significant. The constant score at 3b months was lower, compared to 3 months ASES score. This can be attributed to the difficulty for the patient to

perform strength measurement using dynamometer at 3 months, but at 6 months all the patients had excellent results.

In addition to the risks of surgery such as blood loss, infection, and anesthetic-related issues, rotator cuff surgery complications may include; axillary nerve injury, joint infection, deltoid detachment, stiffness, and re-tear. Our study, fortunately, had no complications like re-tear, stiffness, neurovascular injury, infection, except for the pain at the surgical site for 24 to 48 hours, which was also managed only with NSAIDs. Weber SC and Schaefer R. (23) reviewed the results of mini-open repairs versus those of traditional open repairs in a retrospective study in 1993 and concluded the mini-open-treated group used significantly less parenteral narcotics and had shorter hospital stays as in coherence with our study. Age, gender, smoking, size of the tear, tendon quality, healing of the rotator cuff repair, hyperlipidemia, worker's compensation status, fatty infiltration of the muscle, the traumatic onset of the lesion, obesity, diabetes, multiple tendon involvement, and additional procedures during the rotator cuff repair surgery to the biceps and AC joint are associated with less favorable outcomes after rotator cuff repair. In addition to non-modifiable factors, there are also modifiable factors that are associated with outcomes. Our study has certain limitations, firstly we had a relatively smaller sample size. Secondly, follow-up duration is short as we wanted to study the early functional recovery and the

time when the full range of motion is achieved. Thirdly, radiographic follow-up by ultrasound, MRI may be considered to evaluate the tissue regeneration in subsequent research efforts.

Conclusion

We had excellent results with transosseous mini-open rotator cuff repair. This procedure is cost-effective and is a good treatment option in developing countries, where the affordability of the patients is less. Further studies with a larger number of patients and a longer follow-up will establish the role of transosseous mini-open rotator cuff repair in the treatment of complete rotator cuff tear.

Conflict of Interest: None.

Funding: None.

References

1. Luime JJ, Koes BW, Hendriksen IJM, Burdorf A, Verhagen AP, Miedema HS, et al. Prevalence and incidence of shoulder pain in the general population; a systematic review. *Scand J Rheumatol*. 2004;33(2):73–81.
2. Sher JS, Uribe JW, Posada A, Murphy BJ, Zlatkin MB. Abnormal findings on magnetic resonance images of asymptomatic shoulders. *J Bone Joint Surg Am*. 1995;77(1):10–5.
3. Mitchell C, Adebajo A, Hay E, Carr A. Shoulder pain: diagnosis and management in primary care. *BMJ*. 2005;331(7525):1124–8.
4. Iannotti null. Full-Thickness Rotator Cuff Tears: Factors Affecting Surgical Outcome. *J Am Acad Orthop Surg*. 1994;2(2):87–95.
5. Weber SC. Arthroscopic debridement and acromioplasty versus mini-open repair in the treatment of significant partial-thickness rotator cuff tears. *Arthroscopy*. 1999;15(2):126–31.
6. Park JY, Levine WN, Marra G, Pollock RG, Flatow EL, Bigliani LU. Portal-extension approach for the repair of small and medium rotator cuff tears. *Am J Sports Med*. 2000;28(3):312–6.
7. Black EM, Austin LS, Narzikul A, Seidl AJ, Martens K, Lazarus MD. Comparison of implant cost and surgical time in arthroscopic transosseous and transosseous equivalent rotator cuff repair. *J Shoulder Elbow Surg*. 2016;25(9):1449–56.
8. Robinson PM, Wilson J, Dalal S, Parker RA, Norburn P, Roy BR. Rotator cuff repair in patients over 70 years of age: early outcomes and risk factors associated with re-tear. *Bone Joint J*. 2013;95-B(2):199–205.
9. Khair MM, Lehman J, Tsouris N, Gulotta LV. A Systematic Review of Preoperative Fatty Infiltration and Rotator Cuff Outcomes. *HSS J*. 2016;12(2):170–6.
10. Ohzono H, Gotoh M, Nakamura H, Honda H, Mitsui Y, Kakuma T, et al. Effect of Preoperative Fatty Degeneration of the Rotator Cuff Muscles on the Clinical Outcome of Patients With Intact Tendons After Arthroscopic Rotator Cuff Repair of Large/Massive Cuff Tears. *Am J Sports Med*. 2017;45(13):2975–81.
11. Levy HJ, Uribe JW, Delaney LG. Arthroscopic assisted rotator cuff repair: preliminary results. *Arthroscopy*. 1990;6(1):55–60.
12. Blevins FT, Warren RF, Cavo C, Altchek DW, Dines D, Palletta G, et al. Arthroscopic assisted rotator cuff repair: results using a mini-open deltoid splitting approach. *Arthroscopy*. 1996;12(1):50–9.
13. Baysal D, Balyk R, Otto D, Luciak-Corea C, Beaupre L. Functional outcome and health-related quality of life after surgical repair of full-thickness rotator cuff tear using a mini-open technique. *Am J Sports Med*. 2005;33(9):1346–55.
14. Cho NS, Ha JH, Rhee YG. Patient-controlled analgesia after arthroscopic rotator cuff repair: subacromial catheter versus intravenous injection. *Am J Sports Med*. 2007;35(1):75–9.

15. Paulos LE, Kody MH. Arthroscopically enhanced “miniapproach” to rotator cuff repair. *Am J Sports Med.* 1994;22(1):19–25.
16. Sauerbrey AM, Getz CL, Piancastelli M, Iannotti JP, Ramsey ML, Williams GR. Arthroscopic versus mini-open rotator cuff repair: a comparison of clinical outcome. *Arthroscopy.* 2005;21(12):1415–20.
17. Baysal D, Balyk R, Otto D, Luciak-Corea C, Beaupre L. Functional outcome and health-related quality of life after surgical repair of full-thickness rotator cuff tear using a mini-open technique. *Am J Sports Med.* 2005;33(9):1346–55.
18. Youm T, Murray DH, Kubiak EN, Rokito AS, Zuckerman JD. Arthroscopic versus mini-open rotator cuff repair: a comparison of clinical outcomes and patient satisfaction. *J Shoulder Elbow Surg.* 2005;14(5):455–9.
19. Hanusch BC, Goodchild L, Finn P, Rangan A. Large and massive tears of the rotator cuff: functional outcome and integrity of the repair after a mini-open procedure. *J Bone Joint Surg Br.* 2009;91(2):201–5.
20. Sharma V, Udupudi SV, Sanikop ST, Haveri S, Patil MY. Assessment of functional outcome of mini-open rotator cuff repair: a hospital based prospective study. *International Journal of Research in Orthopaedics.* 2018;4(2):285–90.
21. Angst F, Schwyzer H-K, Aeschlimann A, Simmen BR, Goldhahn J. Measures of adult shoulder function: Disabilities of the Arm, Shoulder, and Hand Questionnaire (DASH) and its short version (QuickDASH), Shoulder Pain and Disability Index (SPADI), American Shoulder and Elbow Surgeons (ASES) Society standardized shoulder assessment form, Constant (Murley) Score (CS), Simple Shoulder Test (SST), Oxford Shoulder Score (OSS), Shoulder Disability Questionnaire (SDQ), and Western Ontario Shoulder Instability Index (WOSI). *Arthritis Care Res (Hoboken).* 2011 Nov;63 Suppl 11:S174-188.
22. Novoa-Boldo A, Gulotta LV. Expectations Following Rotator Cuff Surgery. *Curr Rev Musculoskelet Med* 2018;11(1):162–6.
23. Minimally Invasive Surgery in Orthopedics.pdf [Internet]. [cited 2020 Jan 11]. Available from: http://yengage.yenepoya.edu.in/idata/YenepoyaUniversity/ilFile/2/34/file_23442/001/Minimally%20Invasive%20Surgery%20in%20Orthopedics.pdf