

Esthetic recontouring without esthetic material :

A Case Report

Dr Rashmi Misra

Professor

Department of Conservative Dentistry and Endodontics

D Y Patil School of Dentistry

rashmi.sharma@dypatil.edu

Dr Sumita Bhagwat

Professor

Department of Conservative Dentistry and Endodontics

D Y Patil School of Dentistry

sumita.bhagwat@dypatil.edu

Dr Hitesh Pawar

Senior Lecturer

Department of Conservative Dentistry and Endodontics

D.Y Patil School of Dentistry, Navi Mumbai

Hitesh.pawar@dypatil.edu

Dr Gunjan Pagariya

MDS Ist year

Department of Conservative Dentistry and Endodontics

D.Y Patil School of Dentistry, Navi Mumbai

gunjanpagariya@gmail.com

Dr Vashna Upadhyaya

MDS Ist year

Department of Conservative Dentistry and Endodontics

D.Y Patil School of Dentistry, Navi Mumbai

vashna.upadhyaya@gmail.com

Dr Shriya Verma

MDS IInd year

Department of Conservative Dentistry and Endodontics

D.Y Patil School of Dentistry, Navi Mumbai

shriyaver96@gmail.com

Abstract

With increasing esthetic demand for a perfect smile, providing an ideal smile has become one of the biggest challenges for clinicians.

Esthetic treatment with minimal invasive approach has an advantage in restoring a more natural tooth appearance.

With availability of ample enamel width, we chose to recontour the existing tooth structure without use of any esthetic restorative material.

Patient compliance and out of the box approach were two factors that influenced the

successful clinical outcome.

Introduction

With increasing esthetic demand for a perfect smile, providing an ideal smile has become one of the biggest challenges for clinicians.

Esthetic treatment with minimal invasive approach has an advantage in restoring a more natural tooth appearance. One way is to treat with cosmetic recontouring through enameloplasty.

The aim of this article is to demonstrate a clinical case where a simple approach of cosmetic contouring by enameloplasty with availability of ample enamel recontouring without use of any esthetic restorative material to provide esthetics with optimum occlusal function.

Clinical Report:

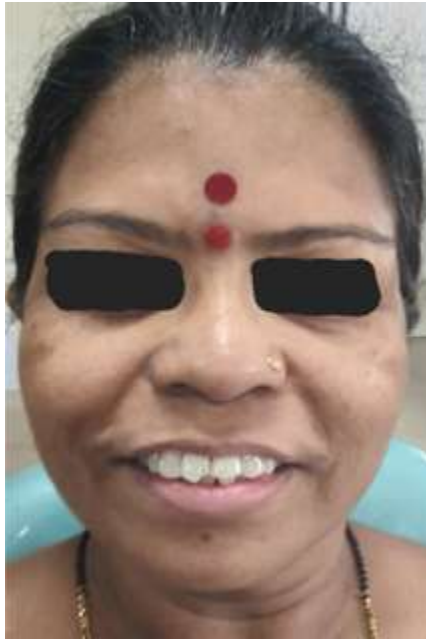A 52 year old female presented with the complaint of fractured maxillary central incisors as a result of trauma 2 years back due to fall, followed by pain and sensitivity for a week, which gradually subsided. No history of pain and sensitivity since then.

On examination ,fractured central incisors 11 ,21 and lateral incisor 22 were noticed.

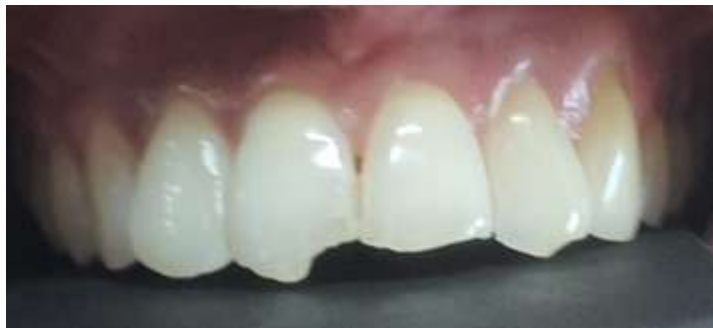11 had fracture involving enamel of mesial half of incisal angle & wear facets on lingual aspect.

21- Fracture involving enamel , loss of incisal edge & wear facets on lingual surface.

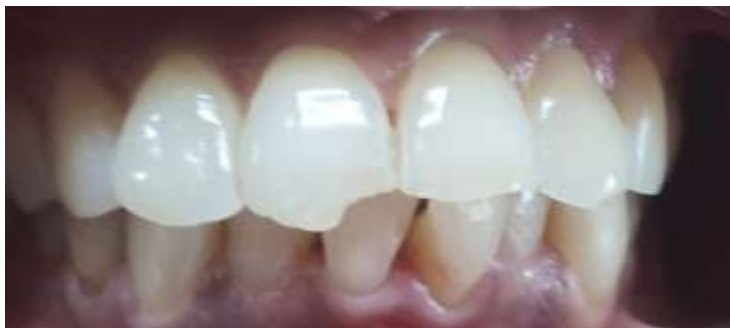22- Fractures involving enamel on incisal edge distally



(A)



(B)



(C)

Fig 1. Preoperative

a.extraoral photograph

b.intraoral photograph of maxillary teeth

c. intraoral photography of occlusion

Patient had bimaxillary protrusion with proclined upper and lower anteriors.

Proclined 31,32,41,42 with 31 rotated and labially tilted. Grade 1 gingival recession (Fig 1.c)

Vitality test was performed with Endofrost for 11,21,22.

Teeth were responsive to cold test similar to that of adjacent and contralateral teeth.

Upper and lower arch impressions were recorded for dimensions of 11,12,21,22 for further treatment planning.

It was diagnosed as Ellis Class 1 fracture with 11,21, 22.

Treatment Plan:

Tooth No	Preoperative Dimensions	Planned Dimensions
11	12.5mm	11mm

12	11.5mm	11mm
21	11mm	11mm
22	12mm	11mm

Treatment protocol included careful analysis of extraoral and intraoral photographs(Fig1) and study models , radiographs, examination of dental and periodontal structure and occlusion. Cosmetic contouring was considered as the treatment of choice for economical and quick esthetic results.

Preoperative dimensions were recorded. A black marker was used to mark the area to be recontoured on the cast. (Fig 3).

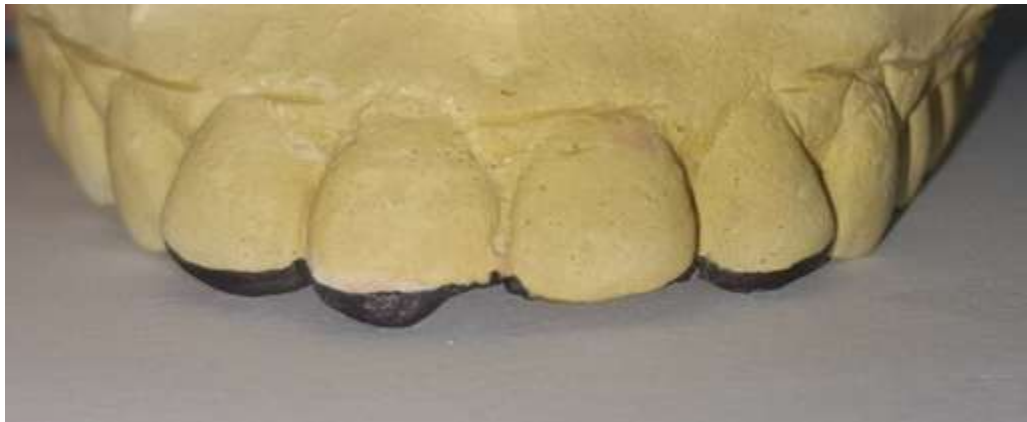

Fig 3. A black marker used to mark the area to be recontoured on the cast, helps in previsualisation of end result

Planned dimensions were recorded.

This aided in previsualisation of the amount of reduction and the end result for the patient.

Treatment Procedure:

Straight diamond bur SF21 (Fig.4.a) was used for initial reduction
11-1.5 mm incisal reduction of distal half till incisal edge of 21
12- 0.5 mm reduction of incisal edge
22- 1mm reduction of incisal edge
12 & 22 were reduced to level of 0.5mm gingival to 11 and 21.
Finishing was done using yellow banded ultrafine TF21EF
diamond finishing bur (Fig 4.b)

For a feminine and softer appearance the distoincisal line angles
of 11,12,21,22 were rounded .This was performed with a Black
coarse disc of Shofu mini snap polishing kit (Fig 4.c) with
waterspray as coolant.

Polishing was completed with Purple(medium),
Green(fine),Pink (extrafine) discs.

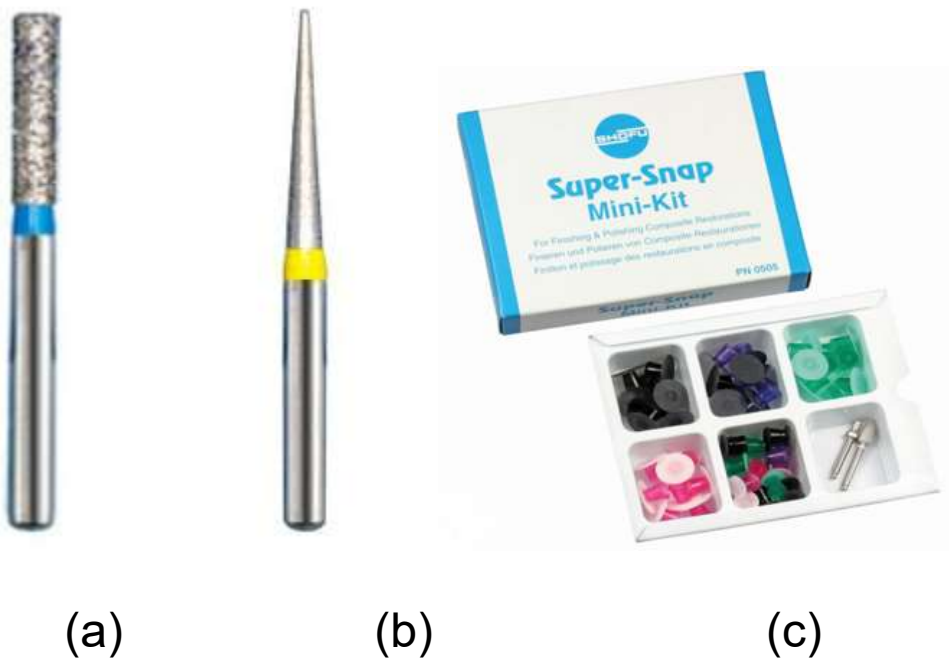


Fig4. a. SF21 straight fissure
b. TF 21 EF diamond finishing bur
c. Shofu mini snap kit

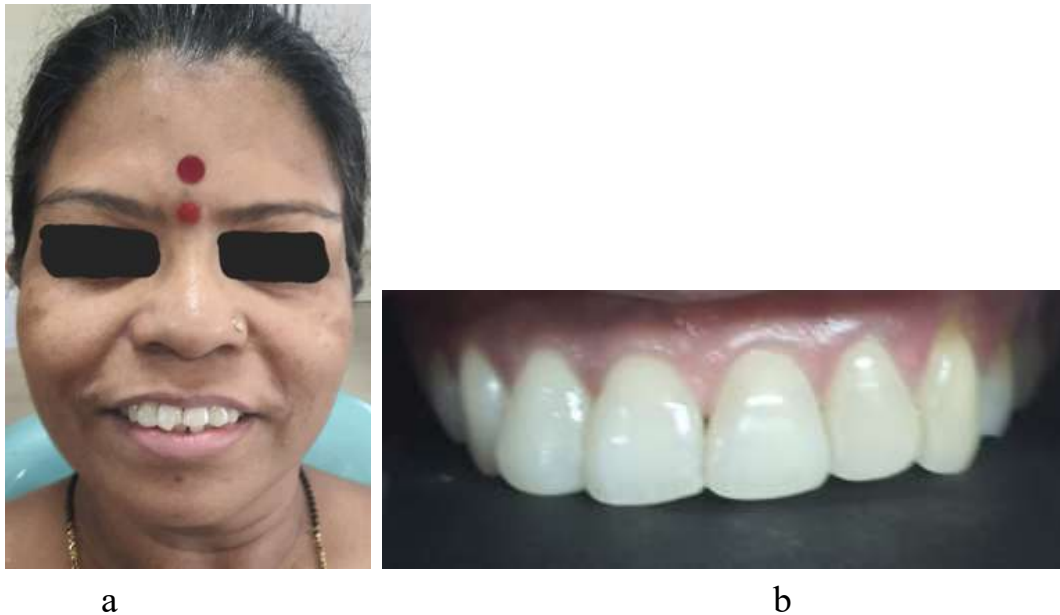


Fig5. Post operative a. Extraoral , b.Intraoral photograph

A topical fluoride application of CPP ACP (GC Tooth Mousse) which delivers 900ppm fluoride was used in trays. Post operative impressions were recorded and post operative instructions were given. Follow up was done. No sensitivity was experienced by the patient.

Discussion:

Cosmetic contouring is the shaping of natural teeth to create an even and esthetic smile. It is one of the most valuable of all esthetic procedures because it renders esthetic as well as functional benefits.¹

It is the most appreciated esthetic procedure because it is painless as local anaesthesia is not required & gives immediate & long lasting results with low cost.¹

Principles:

1)Proportion: The silhouette form is the shape of a tooth as defined by the outline of the tooth, and this, even more than color, governs what most people perceive as either attractive or unattractive. The outline of the tooth is usually determined by the portion of the tooth within the mesiolabial and distolabial line angles. This area defines the perception of how big, long, or short a tooth is. Total perception is gained not only by looking at the tooth but also by looking at the smile and at the entire face. It involves first focusing on the tooth and how the teeth relate to each other and then stepping back and visualizing the smile and its relation to the face and seeing what, if anything, can be done to improve the overall appearance¹

2)Gender differences Dentists have prejudices about what is masculine and feminine, but according to Abrams these prejudices are not substantiated by the facts. In clinical practice, however, one should be aware that rounding teeth can soften the appearance and making the mesioincisal and distoincisal line angles more angular can give a harder, more aggressive look. One should consider these appearances as descriptive rather than gender-specific.¹

3)Occlusion Cosmetic contouring must always be done with the principles of proper occlusion in mind. Nothing should be added or eliminated that will produce occlusal disharmonies.¹

In maxillary anterior teeth, the objectives for centric and protrusive positions and excursions are as follows.

- To reduce destructive forces occurring in these positions.

- To produce optimum contact and to eliminate deflecting contacts. Optimum contact is contact of the greatest possible number of teeth without poor esthetics or undesirable occlusion. Since the optimum mandibular incisal level should be established first, all additional grinding to obtain these objectives should be done on the maxillary teeth. Sometimes there will be a conflict between the amount of reduction that gives optimal function and the amount that gives optimal esthetics. The decision will have to be based on the degree of occlusal dysfunction that will remain, the esthetic importance, and the ultimate health of the dental.¹

Indications:

- 1) Alterations of tooth structure
- 2) Correction of developmental abnormalities
- 3) Substitute for crowning
- 4) Minor orthodontic problems slightly crowded anterior teeth, extruded teeth
- 5) Removal of stains and other discolorations,
- 6) Periodontal problems due destructive occlusal forces
- 7) Bruxism causing wearing of anterior teeth with sharp borders and angles¹

Contraindications :

- 1) Hypersensitive teeth
- 2) Large pulp chambers
- 3) Thin enamel
- 4) Deeply pigmented stain
- 5) Occlusal interferences

- 6) Periodontal involvement
- 7) Susceptibility to caries
- 8) Negative psychological reactions
- 9) Large anterior restorations
- 10) Extensive anterior crowding or occlusal disharmony.¹

In cases of minimal misalignment of teeth, the enameloplasty can be considered safe treatment, with few or no side effects.^{5,6} Patients choice of treatment options is fundamental for the success of any procedure and it must be respected since it involves their psychological, physical and financial aspects.

In this case orthodontic treatment could not be considered due to factors such as age of patient ,longer duration and cost of the treatment ⁸

Traumatic occlusion between 11,21 and 31 contraindicated additive technique like composite buildup.

Hence ,cosmetic contouring by enameloplasty without use of composite resin restorative material was performed as it rendered immediate esthetic results in single session.

The important aspects that led us to this novel approach where presence of sufficient tooth structure, patient compliance and out of the box thinking.

Conclusion:

Selective enamel removal being a minimally invasive method provides excellent esthetic results rendering harmonious smile and enhancing self confidence of patient in a cost effective manner.

An open discussion and validation with the patient is of utmost importance for a successful outcome.

Instead of following routine protocols, sometimes it is beneficial to the patient when the clinician tries a new conservative clinical approach which is also evidence based.

Conflict of interest: The subject matter of this article does not involve any conflict of interests.

References:

- 1) Ronald E. Goldstein's Esthetics in Dentistry 3rd Edition
- 2) Heravi F, Rashed R, Abachizadeh H: Esthetic preferences of the shape of anterior teeth in a posed smile. Am J Orthod dentofacial orthop 2011;139(6):806-14
- 3) Alexandre MIARA, Paul MIARA: A minima treatment for superficial enamel defects J Dentofacial Anom Orthod 2012;15:303
- 4) Juan Carlos Pontons-Melo, Isadora Martini Garcia, Fabrício Mezzomo Collares, Marcos Vargas: Bio-additive and enameloplasty technique for restoring anterior esthetics: 54-month clinical follow-up, June 2020 Quintessence international (Berlin, Germany:1985)51(8):2-9

- 5) Juan Carlos Pontons-Melo,Ronaldo Hirata, Fabrício Mezzomo Collares: Cosmetic recontouring for achieving anterior esthetics, January 2019,The International Journal of Esthetic Dentistry 14(2):134-146
- 6) A Thordarson , B U Zachrisson, I A Mjör: Remodeling of canines to the shape of lateral incisors by grinding: a long-term clinical and radiographic evaluation Am J Orthod Dentofacial Orthop 1991 Aug;100(2):123-32.
- 7) Catherine Galleti : Patients with extensive esthetic requests Some tips for finishing and detailing J Dentofacial Anom Othod2013;16:203.
- 8) C.H.Chu, C.F.Zhang, and L.J.Jin,” Treating a maxillary midline diastema in adult patients- a general dentist’s perspective,” Journal of the American Dental Association, vol,142,no.11,pp.1258-1264,2011.