

# A COMPARATIVE STUDY BETWEEN TRADITIONAL FULL LAMINECTOMIES AND MICROSURGICAL BILATERAL DECOMPRESSION BY UNILATERAL APPROACH IN TREATMENT OF LUMBAR CANAL STENOSIS

Unilateral Approach For Bilateral Decompression

Ashraf Osman<sup>1</sup>, Amr Fathy Gomaa<sup>1</sup>, Hazem Abdelbadee<sup>2</sup>, Ahmed Mohammed Aleslisly<sup>2</sup>, Mostafa Abdellatif<sup>1</sup>

1 Department of Neurosurgery, Faculty of Medicine,  
Fayoum University

2 Department of Neurosurgery, Faculty of Medicine,  
Cairo University

Corresponding Author

Amr Fathy Gomaa  
00201009248020

## ABSTRACT

**Background:** Microscopic unilateral approach for bilateral decompression became an alternative surgery for traditional full laminectomy resulting in better outcomes for patients as well as avoiding extensive bony loss.

**Objective:** to evaluate clinical outcomes of unilateral laminectomy approach for bilateral decompression (ULBD) to those of traditional full laminectomies as a treatment of Lumbar Canal Stenosis (LCS).

**Subjects and methods:** Three-hundred LCS patients were included in the study subdivided into two equally groups. Group A patients operated upon with traditional full laminectomies; group B operated upon with unilateral approach for bilateral decompression. Clinical and radiological data were assessed. VAS score and ODI were used to measure patient-reported outcome.

**Results:** Group A and group B (LCS) had a mean age of  $46.9 \pm 11$  and  $53.2 \pm 6.9$  respectively. There was no statistically significant difference between groups as regards number of levels of decompression ( $p$ -value  $> 0.05$ ). Pre-operative and post-operative clinical assessment for patients were done. Results revealed significant improvement of ODI and VAS for leg pain in both groups where in group I, the mean ODI decreased from  $50.1 \pm 10.1$  to  $27.1 \pm 6.7$ , and the mean VAS decreased from  $8.1 \pm 0.7$  to  $2.9 \pm 1.2$ . Group B, the mean ODI decreased from  $46.7 \pm 9.9\%$  to  $22.5 \pm 11.1\%$ , and the mean VAS decreased from  $7.5 \pm 1.4$  to  $2.5 \pm 1.2$ . As for the back pain, VAS score decreased in group A from  $5.1 \pm 1.4$  to  $4.7 \pm 1.7$  and in group B from  $4.2 \pm 2.1$  to  $2.8 \pm 1.2$ .

**Conclusion:** Both techniques are effective procedures for LCS treatment, however ULBD had better outcome regarding postoperative back pain but with longer length of operation.

**Keywords:** Laminectomy; Lumbar Canal Stenosis, Unilateral lumbar approach .

## Introduction

LCS is one of the most common indications for spine surgery. It can be classified based on either etiological or anatomical causes. Etiological classification may be congenital stenosis or acquired/degenerative, while anatomical classification is mainly according to the site of compression either central, lateral recess or foraminal stenosis.<sup>1</sup> Symptoms of LCS differs depending on site of compression of neural elements; in central LCS, patients experience mainly LL neurogenic claudication, but patients with lateral recess stenosis usually present with radicular pain.<sup>2</sup> After the scientific progress in radiological tools, assessment of LCS and its types became easier. MRI is still the best choice in diagnosis of LCS types and severity.<sup>3</sup>

Conservative management, including medications and physiotherapy is usually recommended before surgery.<sup>4</sup> The traditional surgical approach for LCS was a full decompressive laminectomy with resection of the medial portion of the facet joints to decompress neural foramina. However its efficacy to decompress stenosis and improve symptoms,

some side effects were reported e.g. postoperative back pain due to muscle and tissues fibrosis, and the possibility of iatrogenic instability.<sup>5</sup>

To avoid these complications, minimally invasive techniques have been introduced, such as bilateral laminotomies or ULBD. They are associated with less bleeding, more satisfactory outcome with less postoperative pain and shorter recovery period.<sup>6</sup>

## **Patients and method**

Three-hundred Lumbar Canal Stenosis patients fulfilling the rules of the Declaration of Helsinki 1975 were recruited in this study. The study was prospectively conducted at Cairo University hospitals in the period from June 2019 to June 2020. Ethical committee approval was taken from Cairo University as well as written consent from each subject before the start of the study as well. All patients were subjected to thorough history taking, neurological examination and radiological assessment in form of MRI lumbo-sacral spine and dynamic x-rays lumbo-sacral spine. Pain was assessed before & after operations by using Visual analogue scale & Oswestry disability index. Follow up was done for patients of both groups periodically.

### ***Inclusion criteria***

Patients with first degree degenerative spondylolisthesis and with unilateral lumbar disc prolapse were included in this study.

### ***Exclusion criteria***

Patients with bilateral bony canal stenosis, severe mechanical low back pain, with lytic spondylolisthesis and patients with history of previous lumbar surgery were excluded.

Patients were classified into two groups:

- **Group A:** 150 patients were operated upon by standard full laminectomy. Bilateral dissection of paraspinal muscles sub-periosteally was done. Care was taken not to violate the facet capsules. Bilateral decompression was classically done by Kerrison punches of different sizes, after good dissection of ligamentum flavum to avoid dural injury. Nerve roots were decompressed by removing the medial part of the facet (medial facetectomy); the amount of facet joint resection didn't exceed 50%. Discectomy was done if needed. A small blunt hook was used to ensure that adequate foraminal opening exists.
- **Group B:** 150 patients were operated upon by microscopic bilateral decompression by unilateral approach. Unilateral sub-periosteal separation of muscle tissues was performed. The operative microscope was then used to visualize the operative field. After adequate dissection of ligamentum flavum the ipsilateral lamina was removed with a Kerrison rongeur. Then, the medial portion of the facet joint is trimmed as needed to achieve decompression of the lateral recess. The operative table was angled to provide visualization at the base of the spinous process. A Kerrison rongeur was used to remove the base of the spinous process dorsal to the ligamentum flavum.

After the undercutting maneuver was completed, the ligament flavum was separated from its bony attachments and removed at contralateral side. The foramen was decompressed by resecting the superior tip of the superior articular process as needed to decompress the exiting nerve root. The adequacy of the decompression was confirmed bilaterally by using small blunt hook. Discectomy was done also if needed. Intra-operative assessment of amount of estimated blood loss and duration of surgery was done. Peri-operative complications were observed. Full neurological assessment was performed to all patients to detect improvement or deteriorations of their neurological condition, with a mean follow up period of 12 months. After stabilization patients were discharged from hospital for outpatient clinic follow up visit after two weeks for sutures removal. Another post-operative visits were requested three months, six months and one year in outpatient clinic to assess their neurological status. Post-operative LSS x-rays imaging was done for all patients, CT scan or MRI imaging were done only for patients with no improvement of their back or LL pain.

## **Statistical Analysis**

Data were collected and coded into Microsoft Access and data analysis performed using the Statistical Package of Social Science (SPSS) software version 22 in windows 7 (SPSS Inc., Chicago, IL, USA). Quantitative data included in the study first tested for normality by One-Sample Kolmogorov-Smirnov test in each study group then inferential statistic tests selected, in form of t-test for independent samples to compare quantitative measures between two independent groups and paired t-test used to compare two dependent quantitative data. For qualitative data, Chi square test used to compare between two of more than two qualitative groups. The P-value < 0.05 was considered as statistical significant.

## **Results**

On comparing demographic characteristics of the patients in our study groups, traditional full laminectomy technique was applied to group A. 110 patients were males and 40 were females, with a mean age of  $46.9 \pm 11$  years. Microscopic ULBD technique was conducted on group B, 140 patients were males and 10 were female with a mean age of  $53.2 \pm 6.9$  years. There was no statistically significant difference with  $p$ -value  $> 0.05$  between two study groups as regards age and sex.

On analysis of number of levels of decompression, in group A, the majority of cases (50 cases, 33.3%) were operated upon by 3 levels of decompression with a mean  $2.9 \pm 1.3$  levels (Figure 1). In group B, the majority of cases (80 cases, 53.3%) were operated upon by 2 levels of decompression with a mean  $2.3 \pm 0.9$  levels. There was no statistically significant difference with  $p$ -value  $> 0.05$  between both study groups as regards number of levels of decompression (Table 1).

On comparing pre-operative clinical assessment of patients in group A, the average of VAS for leg pain was  $7.5 \pm 1.4$  and for back pain was  $4.2 \pm 2.1$  with average ODI  $50.1 \pm 10.1\%$ . In group B, the average of VAS for leg pain was  $8.1 \pm 0.7$  and for back pain was  $5.1 \pm 1.4$  with average ODI  $46.7 \pm 9.9\%$  (Figure 2&3). There was no statistically significant difference with  $p$ -value  $> 0.05$  between both study groups as regards VAS score and Oswestry disability index before operation.

Regarding the duration of surgery needed in both groups. In group A, a mean operative time of  $2.7 \pm 0.56$  hours was needed, in group B; a mean operative time of  $3.7 \pm 1.2$  hours was needed. Estimated intraoperative blood loss in group A had an average of  $360 \pm 107.2$  mL but in group B, it was  $300 \pm 75.6$  mL.

There was a statistically significant difference with  $p$ -value  $< 0.05$  between both study groups as regards duration of operation with longer operation duration among group B. On the other hand, there is no statistically significant difference with  $p$ -value  $> 0.05$  as regards estimated blood loss volume.

On comparing postoperative clinical improvement after 1 year of both groups, in group A, the mean postoperative VAS for LL pain improved to  $2.9 \pm 1.2$ , VAS for back pain was  $4.7 \pm 1.7$  and the mean ODI was  $27.1 \pm 6.7\%$ . While in group B, the mean postoperative VAS for LL pain was  $2.5 \pm 1.2$ , for back pain was  $3.5 \pm 1.2$  and the mean ODI was  $22.5 \pm 11.1\%$ . This indicates a statistical significant lower mean postoperative VAS back score among group B, with no statistically significant difference with  $p$ -value  $> 0.05$  between both study groups as regards VAS leg score and Oswestry disability index after operation.

On comparing preoperative and postoperative assessment of clinical condition of patients of our study groups, revealed significant improvement of ODI and VAS for leg pain in both groups. In group A, the mean ODI decreased from  $50.1 \pm 10.1\%$  to  $27.1 \pm 6.7\%$ , and the mean VAS for leg pain decreased from  $8.1 \pm 0.7$  to  $2.9 \pm 1.2$ . In group B, the mean ODI decreased from  $46.7 \pm 9.9\%$  to  $22.5 \pm 11.1\%$ , and the mean VAS for leg pain decreased from  $7.5 \pm 1.4$  to  $2.5 \pm 1.2$ . While the mean VAS for back pain decreased in group A, from  $5.1 \pm 1.4$  to  $4.7 \pm 1.7$  and in group B significantly decreased from  $4.2 \pm 2.1$  to  $2.8 \pm 1.2$  (Table 2).

Regarding postoperative hospital stay, average hospital stay in group A of our study was  $3.2 \pm 1.5$  days (range: 2-8 days). In group B, average hospital stay was  $3.1 \pm 1.4$  days (range: 2-7 days). The difference was not statistically significant.

When documenting incidence of intra and post-operative complications, we found the following, in group B there were 20 patients complicated with dural tears which primary repaired intraoperative with no CSF leak or postoperative complications. Also one patient developed lumbar instability after one year postoperatively and he needed lumbar fixation.

In group B, there were 20 patients complicated with dural tear, one of them we could do primary repair for the tear but the second one we couldn't, as it was a small dural tear in the lateral aspect of the thecal sac, managed with putting a fat graft, blood patch and gel foam over it, with no CSF leak or postoperative complications. This results showed no statistically significant difference with  $p$ -value  $> 0.05$  between both study groups as regards postoperative complications.

### Discussion

Degenerative lumbar canal stenosis is the most common cause for low back pain in people older than 65 years. For properly selected patients, decompressive surgery offers an advantage over conservative treatment. Therefore, it is important to choose the optimal method of treatment to suite the individual patient requirements and proper patient counseling.<sup>7</sup>

We compared between ULBD technique and standard full laminectomy technique. In our study there was no statistically significant difference between both comparative studies groups regarding the baseline demographic data and preoperative clinical assessment of patients using VAS score and Oswestry disability index. This augments accuracy of end results and decreases bias toward positive results of study groups.

On analysis of number of levels of decompression, in our study, the majority of cases were operated by 2 levels. This goes with the study described by Bradley K. in which also included 30 cases, the majority of them were operated by 2 levels.<sup>8</sup> In our study, 3 cases also were operated by 4 levels and 3 cases were operated by 5 levels. Some authors excluded long segments decompression more than 3 levels from their studies because of difficulty of operating these cases by microscopic ULBD technique.

On analysis of average of the total length of operations, it was significantly higher in group B than group A similar to Khoo and Fessler who reported an operative duration of 109 minutes for a single level micro-endoscopic unilateral laminotomy and 88 minutes for open laminectomy.<sup>9</sup> Contrary to Rahman et al who documented that ULBD approach involves shorter operating times than open decompressive technique.<sup>10</sup> The increased operation time in the microscopic technique in our study was due to the steep learning curve for manipulating instruments through a small field space and for adequate decompression without complications.

Our study results revealed a statistically high significant postoperative improvement among both groups in VAS leg score and ODI score. In addition, group B achieved a significantly greater improvement as regard VAS back score, but in group A, there was no statistically significant change with p-value >0.05. However, on comparing both groups the difference was not statistically significant as regard outcome improvement in ODI and VAS leg scores.

Our results matches with study of Mobbs et al who showed that postoperative ODI and VAS leg scores showed statistically significant improvements in each group. However, there was no significant difference between both groups as regard postoperative VAS scores and ODI.<sup>11</sup> In contrary, Thomas et al compared outcomes of 14 patients with laminotomies and 12 with laminectomies and showed a higher reduction of back and leg pain in the full laminectomies group.<sup>12</sup>

By combining our results of number of levels, length of operation and postoperative clinical outcome, our recommendation regarding long segment decompression (3 levels or more) is that ULBD technique has good outcome for those patients complaining mainly from LL claudication pain, with less postoperative back pain and less incidence of iatrogenic instability (as in cases with preoperative 1<sup>st</sup> degree degenerative spondylolisthesis). But unfortunately, this needs considerable experience and long term training on this approach to achieve adequate decompression with low rate of complications. Also ULBD approach couldn't be applied on patients with severe bilateral bony stenosis who required standard bilateral laminectomies and patients with unstable medical conditions that made them unfit for longer time of general anesthesia.

Regarding post-operative instability after one year postoperatively, 6.7% patients in group A developed severe back pain, not improved by conservative management due to lumbar instability so re-operated again by fixation (Figure 4&5). Epstein's study revealed that progression from Grade I to Grade II spondylolisthesis at the 2 years follow up was seen in 31.4% of cases.<sup>13</sup>

## Conclusion

Unilateral approach for bilateral decompression is a good option instead traditional full laminectomy better outcomes as regards postoperative pain, and it was found to respect the posterior spinal integrity and musculature, accompanied with less blood loss, shorter hospital stays, and shorter recovery periods than the open laminectomy technique. Although it needs to be more practiced to ensure its performance in less operating time.

## Contribution Details

Ashraf Osman and Amr Fathy Gomaa had the main idea, concept, design of this study. Hazem Abdelbadee and Mostafa Abdellatif contributed the definition of intellectual content as well as the literature search. Amr Fathy Gomaa, Ashraf Osman and Ahmed Mohammed Alselisly assessed the clinical studies as well as the data acquisition. Data Analysis and statistical Analysis were done by Amr Fathy Gomaa and Mostafa Abdellatif. All authors analyzed and discussed the data. All authors contributed in the manuscript preparation, editing and review .

## Figures Legends

Figure 1: MRI LSS sagittal & axial cuts, preoperative images (pre): Showing LCS at L2-3-4, postoperative images (post): showing well decompressed L2-3-4 levels.

Figure 2: Comparisons of preoperative VAS score in study groups.

Figure 3: Mean preoperative ODI in study groups.

Figure 4: 1 year post-decompression dynamic LSS x-rays (A-flexion, B-extension views, showing L3-4 instability mainly in flexion view.

Figure 5: CT LSS axial cuts of L3-4 facet joints of patient who needed lumbar fixation after 1 year; showing that previous facet bone resection in 1<sup>st</sup> operation was less than 50%.

## References

1. Kapoor R, Kumar B, Singh MR. Evaluation of wide interlaminar fenestration surgery in degenerative lumbar canal stenosis. *International Journal of Orthopaedics* 2017; 3: 607-613.
2. Allegri M, Montella S, Salici F, Valente A, Marchesini M, Compagnone C, et al. Mechanisms of low back pain: A guide for diagnosis and therapy 2016; 5: F1000.
3. Schroeder GD, Kurd MF, Vaccaro AR. Lumbar spinal stenosis: How is it classified? *J Am Acad Orthop Surg* 2016; 24: 843-852.
4. Zaina F, Tomkins, Lane C, Carragee E, Negrini S. Surgical versus nonsurgical treatment for lumbar spinal stenosis. *Spine* 2016; 41: 857-868.
5. Bresnahan L, Ogden AT, Natarajan RN, Fessler RG. A biomechanical evaluation of graded posterior element removal for treatment of lumbar stenosis: Comparison of a minimally invasive approach with two standard laminectomy techniques. *Spine* 2009; 34:17-23.
6. Shamji MF, Goldstein CL, Wang M, Uribe JS, Fehlings MG. Minimally invasive spinal surgery in the elderly: Does it make sense?. *Neurosurgery* 2015; 77(4):108-115.
7. Thamer A Hamdan, Ahmad S Abdul Hassan. Spinal Instability following Multilevel Decompressive Laminectomy without Fusion for Degenerative Lumbar Canal Stenosis. *World J Surg Surgical Res* 2020; 3: 1193.
8. Bradly K, Weiner, Walker M, Brower R, McCulloch JA. Microdecompression for lumbar spinal canal stenosis. *Spine* 1999; 24(21): 2268–2272.
9. Khoo LT, Fessler RG. Microendoscopic decompressive laminotomy for the treatment of lumbar stenosis. *Neurosurgery*. 2002;51(5):S146-S154.
10. Rahman M, Summer LE, Richter B, Mimran R, Jacob RP: Comparison of techniques for decompressive lumbar laminectomy: the minimally invasive versus the classic open approach. *Minim Invasive Neurosurgery*. 2008; 51(2): 100-105.
11. Mobbs R, Li J, Sivabalan P, Raley D, Rao P. Outcomes after decompressive laminectomy for lumbar spinal stenosis: comparison between minimally invasive unilateral laminectomy for bilateral decompression and open laminectomy. *J Neurosurg Spine* 2014; 21(2): 179-186.
12. Thomas NW, Rea GL, Pikul BK, Mervis LJ, Irsik R, McGregor JM. Quantitative outcome and radiographic comparisons between laminectomy and laminotomy in the treatment of acquired lumbar stenosis. *Neurosurgery* 1997; 41(3): 567-575.
13. Epstein NE. Lumbar laminectomy for the resection of synovial cysts and coexisting lumbar spinal stenosis or degenerative spondylolisthesis: an outcome study. *Spine* 2004; 29(9):1049–1056.

Figures

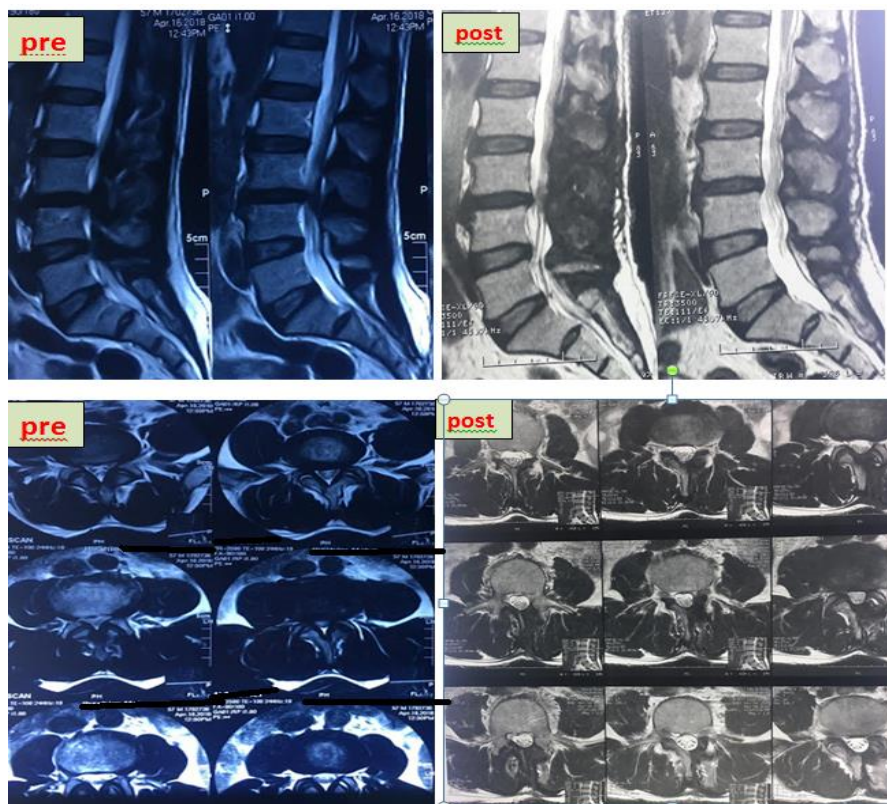


Figure 1: MRI LSS sagittal & axial cuts, preoperative images (pre): Showing LCS at L2-3-4, postoperative images (post): showing well decompressed L2-3-4 levels.

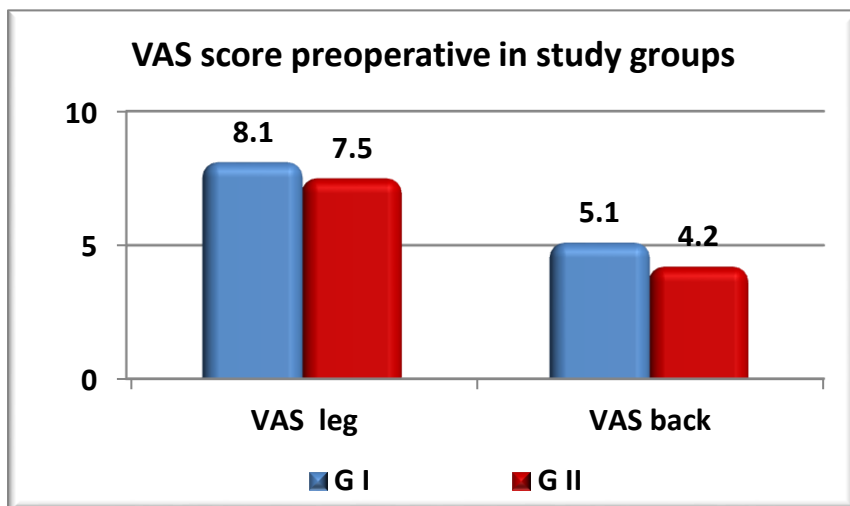


Figure 2: Comparisons of preoperative VAS score in study groups.

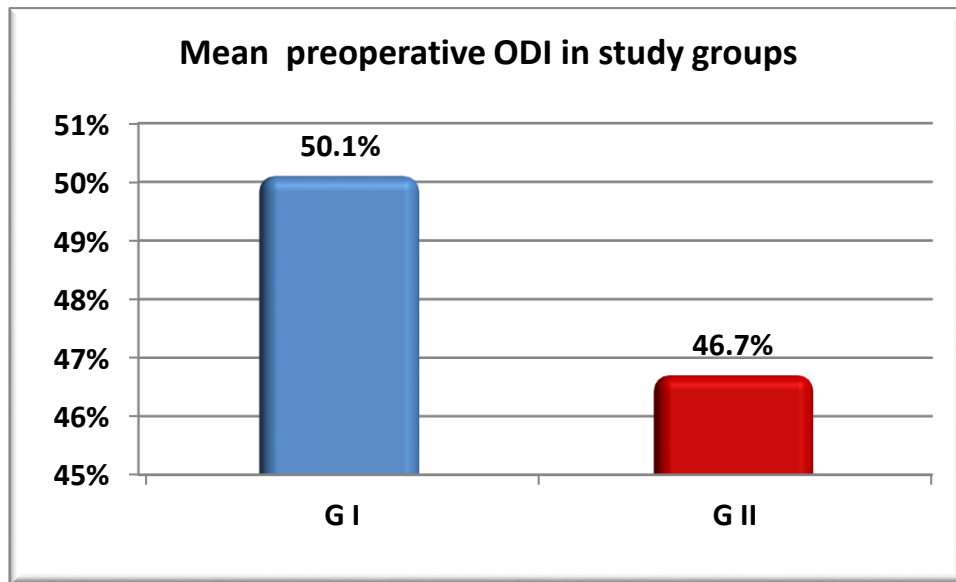


Figure 3: Mean preoperative ODI in study groups.



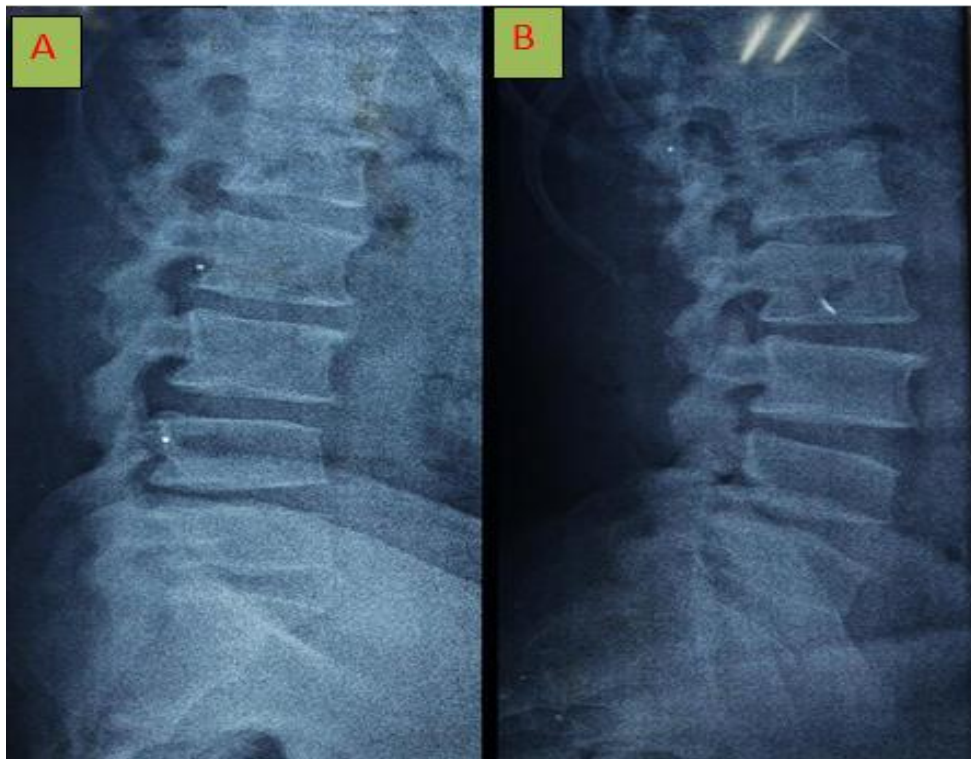

Figure 4: 1 year post-decompression dynamic LSS x-rays (A-flexion, B-extension views, showing L3-4 instability mainly in flexion view).

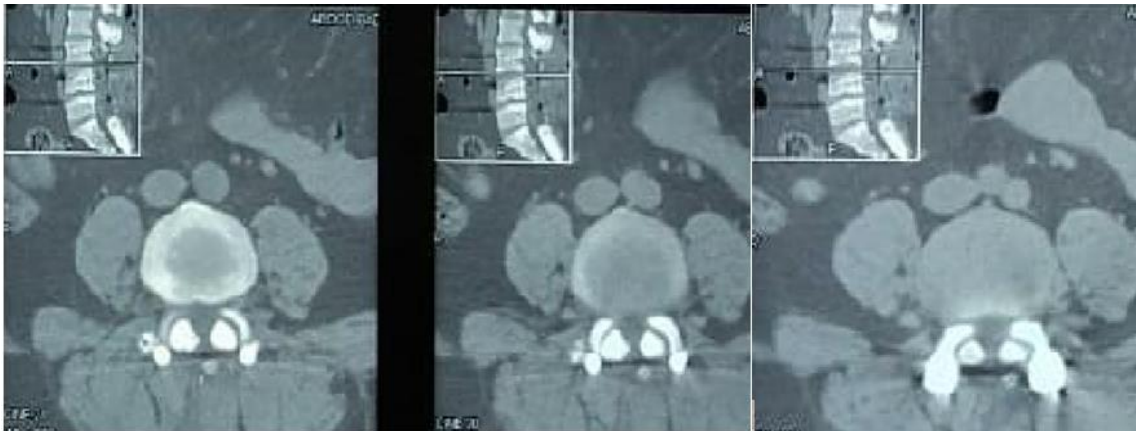


Figure 5: CT LSS axial cuts of L3-4 facet joints of patient who needed lumber fixation after 1 year; showing that previous facet bone resection in 1<sup>st</sup> operation was less than 50%.

Tables

Table 1: Comparisons of number of levels of decompression in different study groups.

| Variables               | Group A |      | Group B |       | P-value |
|-------------------------|---------|------|---------|-------|---------|
| <b>Number of levels</b> |         |      |         |       |         |
| Mean /SD                | 9       | 3    | 3       | 9     | 16      |
| <b>Number of levels</b> |         |      |         |       |         |
| One                     |         | 3.3% |         | 3.3%  | 27      |
| Two                     |         | 6.7% |         | 6.7%  |         |
| Three                   |         | 3.3% |         | 20%   |         |
| Four                    |         | 6.7% |         | 13.3% |         |
| Five                    |         | 0%   |         | 0%    |         |

**Table 2: Comparisons of pre and postoperative VAS score and Oswestry disability index in each study groups.**

| Variables      | Pre-operative |      | Post-operative |      | P-value      |
|----------------|---------------|------|----------------|------|--------------|
|                | mean±SD       |      |                |      |              |
| <b>Group A</b> |               |      |                |      |              |
| VAS leg        | 17            | 7    | 9              | 2    | <b>0.001</b> |
| VAS back       | 14            | 4    | 7              | 7    | 0.33         |
| DI             | 0.1%          | 0.1% | 0.1%           | 0.7% | <b>0.001</b> |
| <b>Group B</b> |               |      |                |      |              |
| VAS leg        | 15            | 4    | 5              | 2    | <b>0.001</b> |
| VAS back       | 12            | 1    | 3              | 2    | 0.03         |
| DI             | 0.7%          | 0.9% | 0.5%           | 0.1% | <b>0.001</b> |