

## Varicose Veins Treated with Endovenous Laser Ablation – A Retrospective And On- Going Prospective Observational Study

Dr Rajesh G Patil<sup>1</sup>, Dr Parth Mulgaokar<sup>2</sup>, Dr Preksha Sharma<sup>3</sup>

<sup>1</sup>Associate Professor, Department of General Surgery, Byl Nair Charitable Hospital, Mumbai.

<sup>2</sup>Senior Resident, Department of General Surgery, Byl Nair Charitable Hospital, Mumbai.

<sup>3</sup>Junior Resident, Department of General Surgery, Byl Nair Charitable Hospital, Mumbai.

Corresponding Author: Dr Rajesh G Patil

### Abstract:

#### Background:

Varicose vein is a common surgical disease. Diagnosis and management of the same has significantly improved since the advent of Duplex Ultrasonography. This study was undertaken to evaluate the clinical outcomes in patients with varicose veins treated with Endovenous Laser Ablation (EVLA).

#### Materials and Methods:

This retrospective and on-going prospective observational study was carried out in a tertiary care centre for a period of 18 months. Study included total 80 patients who underwent EVLA for varicose veins fulfilling inclusion and exclusion criteria. Demographic data (age, gender), clinical signs and symptoms, USG doppler findings, operative findings, and post-operative complications were recorded.

#### Results:

In this study, mean age of study patients was  $44.66 \pm 14.33$  years with a range from 21 to 69 years, and male preponderance (81.2%). Standing for long duration was reported in 85% of study patients, and in 80% of patient duration of disease was less than from 1 to 5 years. Dilated veins were common clinical presentation seen in 80% patients. In most of patients, hospital stay was  $\leq 4$  days. Nerve injury (27.5%) and anesthetic complications (27.5%) were the most common complications seen in this study.

#### Conclusion:

EVLA is a safe and reliable minimally invasive procedure to treat varicose vein diseases with minimal post-operative complications.

**Key words:** Endovenous laser treatment, Great saphenous veins, Varicose veins

#### Introduction

Lower limb varicose veins are the commonest of all vascular disorders. Considerable advances in understanding of pathophysiology of venous disease and modern imaging techniques, in particular color duplex ultrasonography, have revolutionized the concept of management of varicose veins.[1,2] Data suggest that chronic venous insufficiency has a significant impact

on the population, both in terms of the quality of life and the number of people affected by the disease. Chronic venous insufficiency has a varied presentation from asymptomatic state to varicose veins, oedema, skin changes, and ulceration. Varicose veins are found in up to 20% to 30%, skin changes in up to 6%, and active venous ulcerations in up to 0.5% of the population. Clinical presentation is also coupled with variable impacts on quality of life ranging from cosmetic concerns to debilitating symptoms and limb- and life-threatening complications.[3-5]

Patients undergoing Varicose veins stripping surgery are associated with complication like increased risks to develop a wound infection, seroma formation and rarely permanent lymphoedema of the leg. For these reasons it might be worth considering other therapies like foam Sclerotherapy, Radiofrequency Ablation (RFA), and Endovenous Laser Ablation (EVLA). Endothermal ablation technologies replaced surgical ligation and stripping as the gold standard treatment once randomized trials demonstrated that they were marginally safer, have extremely high technical efficacy, offer superior quality of life post procedure (with a rapid recovery) and equivalent improvements in quality of life in the longer term. The techniques are cost effective as they can be performed under a single sitting of spinal anesthesia/tumescent anesthesia. The patient can be discharged ambulatory on the day of the surgery in day care.[6-9] This study aimed to evaluate the clinical outcomes in patients with varicose veins treated with EVLA, in order to investigate its potential as the primary modality for treating Varicose veins in future.

### **Materials and Methods:**

This retrospective and on-going prospective observational study was carried out in a tertiary care centre for a period of 18 months, after obtaining approval from the institutional ethics committee . Written informed consent was obtained from each patient prior to their enrollment in study. Study included total 80 patients undergoing EVLA for varicose veins fulfilling inclusion and exclusion criteria.

### **Inclusion Criteria:**

- Age >18yrs, either sex, elective admission
- Symptomatic Great Saphenous Vein (GSV) reflux (primary or recurrent) confirmed by duplex imaging
- Associated Small Saphenous Vein (SSV) reflux on duplex imaging
- Varicose veins without GSV or SSV incompetence on duplex imaging

**Exclusion criterion:**

- Age <18yrs
- Deep Vein Thrombosis
- Superficial thrombophlebitis
- Pregnancy
- Isolated varicosities
- Residual perforator
- Recurrent perforator
- Previous history of Endovenous laser therapy & foam sclerotherapy
- Foam sclerotherapy

**Methodology:**

Enrolled patients were admitted in ward and required clinical examination was performed including following tests:

1. Brodie Trendelenbergs Test: To check for Sapheno-Femoral valve incompetence.
2. Multiple-tourniquet Test: To check the individual incompetent perforator site.
3. Modified Perthe's Test: To check for the presence of Deep Vein Thrombosis.

**Procedure:**

Patient was taken in operation theatre and local/spinal anaesthesia was given. Under absolute aseptic precautions, parts were painted and draped from umbilicus to toes. Cannulation of the greater saphenous vein (GSV) was done with 16G needle under ultrasonography (USG) guidance after reconfirming no evidence of Deep vein thrombosis. Back flow in intravenous cannula was checked. After checking back flow, guide wire was passed along the length of the GSV. Presence of guidewire in the lumen of the cannulated vein was checked with the USG probe. A small incision was taken at the site of insertion of the iv cannula to aid the passage of dilator and the sheath. IV cannula was carefully withdrawn and dilator was inserted over the guidewire. Careful removal of the dilator was followed by insertion of sheath for laser

fibre. SFJ was confirmed with USG probe. Mickey Mouse sign was seen on USG. Through the sheath, a radial laser fibre was passed along the length of GSV just 3-5cm distal to the Sapheno-Femoral Junction (SFJ). The tumescence mixture (10cc of 2% lignocaine with 10cc Soda Bicarbonate in 480ml 0.9N Normal Saline) was infiltrated in the saphenous fascia up to the laser fibre in GSV. Laser fibre was used with a radial Wavelength of 1470nm. Energy delivery was according to size of vein. After Ablation of the vein hemostasis at the puncture site was checked along with any skin changes along the length of GSV. Small subcutaneous veins were treated with foam sclerotherapy on outpatient basis. Grade 2 Varicose stocking were applied to keep tamponade effect on small subcutaneous veins treated with sclerotherapy and to prevent recanalization of ablated main vein. Post operatively single dose of iv antibiotics with anti-inflammatory and multivitamin supplement were given. Patient was discharged on the same day or the next day and told to follow up on outpatient basis for evaluation of post-surgical outcome. Patient was followed up at 1, 4 and 12 weeks post the procedure. A Doppler ultrasonography was done for the limb treated with EVLA to corroborate the physical findings. The patient was followed up for symptoms like pain, visible limb vein, swelling, skin changes, ulcer, tingling numbness and recurrent varicosities.

For retrospective analysis, record of patients who underwent EVLA for varicose veins were assessed. Demographic data (age, gender), duration of disease and hospital stay, clinical signs and symptoms, USG doppler findings, operative findings, and post-operative complications were recorded in all the patients.

### **Results:**

In this study, mean age of study patients was  $44.66 \pm 14.33$  years with a range from 21 to 69 years. Majority of patients were in the age group of 41-60 years (50%). Out of 80 patients, 65 were male and 15 were female. Diabetes (20%) was the most common co-morbidity observed in study patients, followed by hypertension (10%). Long duration of standing was reported in 85% of study patients, and only 5% patients had a positive family history varicose vein. In 80% of patients, duration of disease was between 1 year and 5 years. (Table 1)

**Table 1: Demographic and Clinical parameters in study patients**

<b>Parameters</b>		<b>Number</b>	<b>Percentage</b>
<b>Age (Years)</b>	21-40	28	35
	41-60	40	50
	>60	12	15
<b>Gender</b>	Male	65	81.2

	Female	15	18.8
<b>Co-morbidities</b>	Diabetes	16	20
	Hypertension	8	10
	HIV	4	5
	CVA	4	5
<b>Long duration of standing</b>	Yes	68	85
	No	12	15
<b>Positive Family History</b>	Yes	4	5
	No	76	95
<b>Duration of Disease (Years)</b>	1-5	64	80
	5-10	4	5
	>10	12	15

Dilated veins were seen in 80% patients, followed by skin changes in 70.0% patients, oedema in 65% patients, evening pain in 60% patients, active ulcer in 38.8% patients and reti/spider veins in 15% patients. (Table 2)

**Table 2: Clinical presentation of patients with varicose veins**

<b>Clinical presentation</b>	<b>Number</b>	<b>Percentage</b>
Dilated veins	64	80.0
Skin changes	56	70.0
Oedema	52	65.0
Evening pain	48	60.0
Active ulcer	31	38.8
Reti / spider veins	12	15.0

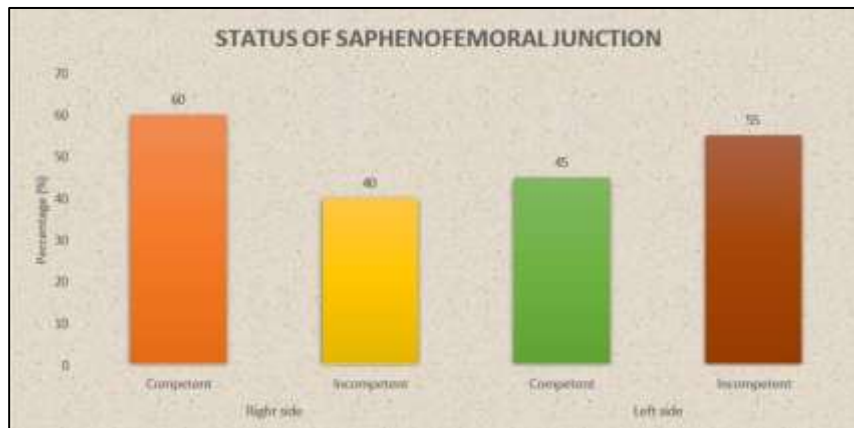
In this study, bilateral affected limb was observed in 35% patients, left lower limb was affected in 35% patients and right lower limb was affected in 30% patients. In 60% of study patients, right lower limb was treated and in 40% patients left lower limb was treated during study period. In most of patients, hospital stay was  $\leq 4$  days. (Table 3)

**Table 3: Distribution according to Affected Limb and Treated Limb**

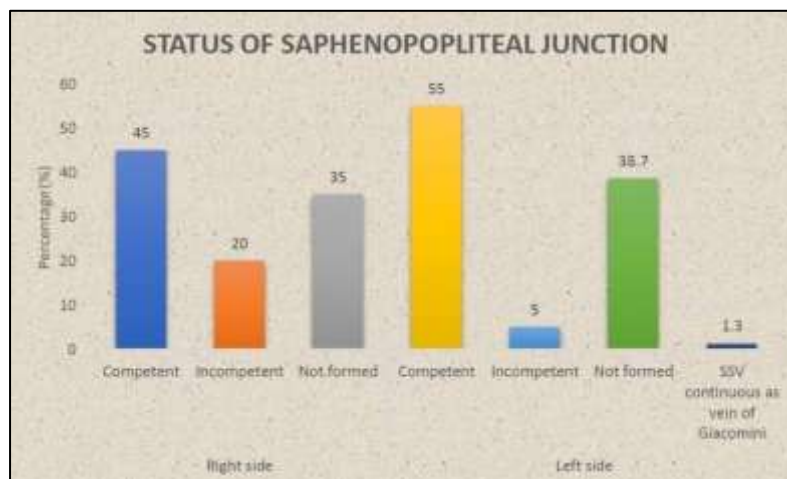
		<b>Number</b>	<b>Percentage</b>
<b>Affected Limb</b>	Bilateral	28	35
	Left	28	35
	Right	24	30
<b>Treated Limb</b>	Left	32	40
	Right	48	60
<b>Duration of Hospital stay (days)</b>	2-4	64	80.0
	5-6	16	20.0

The right side saphenofemoral junction (SFJ) was competent in 60.0% patients, left side SFJ was competent in 45.0%, suggesting higher incompetence on left side. (Figure 1) The right side saphenopopliteal junction (SPJ) was competent in 45% of patients, incompetent in 20% patients and not formed in 35% patients. The left side SPJ was competent in 55%)

patients, incompetent in 5% patients, not formed in 38.7% patients and SSV was continuous as vein of Giacomini in 1.3% patients. (Figure 2)



**Figure 1: Status of SFJ in study patients**



**Figure 2: Status of Sapheno-popliteal Junction in study patients**

In this study, mean maximum and minimum diameter of GSV by color doppler was  $7.10 \pm 3.21$  mm and  $3.30 \pm 1.24$  mm, respectively. On the other hand, mean maximum SSV was  $3.46 \pm 1.64$  mm and mean minimum SSV was  $2.19 \pm 1.26$  with a range from 0.6 to 5.4. (Table 4) Distribution of patients according to CEAP Classification is presented in Table 5.

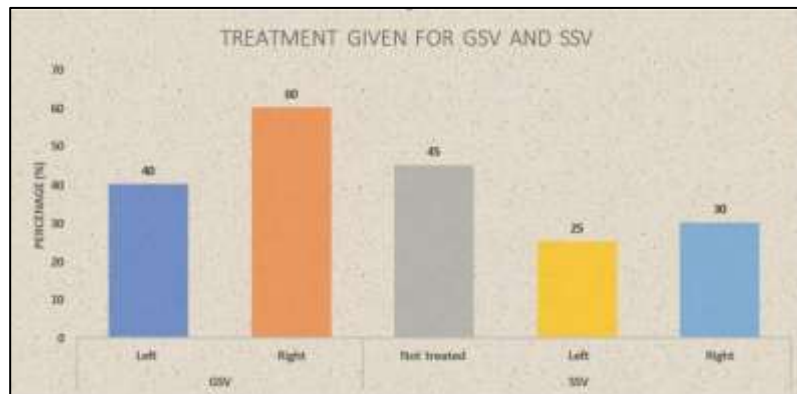
**Table 4: Mean values of Color Doppler of GSV (mm) and SSV (mm)**

	Color Doppler	Mean $\pm$ SD	Lowest Value	Highest Value
GSV (mm)	MAX	$7.10 \pm 3.21$	4.4	21.6
	MIN	$3.30 \pm 1.24$	1.7	6.5
SSV (mm)	MAX	$3.46 \pm 1.64$	1.6	7.0
	MIN	$2.19 \pm 1.26$	0.6	5.4

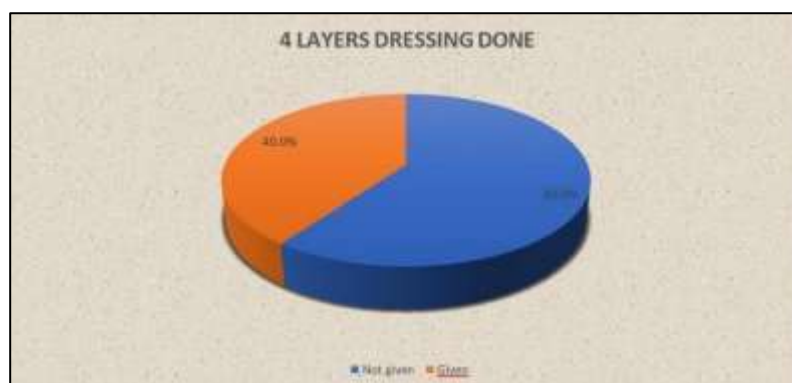
**Table 5: Distribution according to CEAP Classification**

CEAP Classification (2020)		Number	Percentage
C0	No visible or palpable signs of venous disease		
C1	Telangiectasis or reticular veins		
C2	Varicose veins	16	20.0
C2r	Recurrent varicose veins		
C3	Edema	8	10.0
C4	Changes in skin and subcutaneous tissue secondary to chronic venous disease	24	30.0
C4a	Pigmentation or eczema		
C4b	Lipodermatosclerosis or atrophic blanche		
C4c	Corona phlebectatica		
C5	Healed	32	40.0
C6	Active venous ulcer		
C6r	Recurrent active venous ulcer		

The mean energy required for treatment of left GSV was  $3219.88 \pm 604.24$  J and for right GSV was  $4072.65 \pm 997.26$  J. The mean energy required for treatment of left SSV was  $1010.60 \pm 64.71$  J and for right SSV was  $1054.83 \pm 103.99$  J. (Figure 3) Four-layer dressing was given in 40% of study patients. (Figure 4)



**Figure 3: Distribution of study patients according to Treatment given for GSV and SSV**



**Figure 4: Distribution of study patients according to 4 layers Dressing**

Nerve injury (27.5%) and anesthetic complications (27.5%) were the most common complications seen in this study, followed by edema (10%), thrombophlebitis (10%), ulceration at needle entry (6.3%), cellulitis (5%), and recanalization (1.3%). (Table 6)

**Table 6: Distribution according to complications**

Complications	Number	Percentage
Nerve injury	22	27.5
Anesthetic complications	22	27.5
Edema	8	10.0
Thrombophlebitis	8	10.0
Ulceration at needle entry	5	6.3
Cellulitis	4	5.0
Recanalization	1	1.3
DVT	0	0.0

### Discussion:

Varicose vein is a common surgical disease. Diagnosis and management of the same has significantly improved since the advent of Duplex Ultrasonography (both diagnostic and therapeutic). EVLA as a treatment for varicose veins was first described in 2001 and involves the insertion of a laser fiber into the lumen of an incompetent truncal vein, with subsequent thermal ablation of the vein. The vast majority of patients with primary and recurrent varicose veins are suitable for EVLA, with success reported in treating the long, short and anterior saphenous veins, perforators and superficial varicosities themselves.[10-12] This study was undertaken to evaluate the outcomes in patients with varicose veins treated with EVLA.

In this study, majority of the patients were in the age group 41-60 years and the mean age of study patients was  $44.66 \pm 14.33$  years with a range between 21 to 69 years. Malhotra SL et al[14] and Wright et al[15] have observed the age range of 18-65 years and 20-75 years in their respective studies. Male preponderance was observed among patients in this study. Other studies from India have also shown male dominance among varicose veins patients.[13,14,16] Male patient preponderance was seen in this study population due to the socio-economic trends in the Indians, wherein, women are often neglected or are not able to come to the hospital in spite of high prevalence of the disease in women, as shown by other studies done in the western population.[17-19]

Occupation involving long standing hours increases the duration of venous hypertension. 85% of patients in our study were in the occupation that required long duration of standing. Diabetes (20%) and hypertension (10%) were the commonly observed co-morbidity in this study. Majority of the patients (80%) required short hospital stay for the

treatment of varicose veins in our study. All cases have been conducted Spinal Anesthesia; hence the patient was kept in the hospital for at least one day post operatively. In addition to the short hospital day, patients requiring 5-6 days of hospital stay were on account of the time needed to complete the procedure for complete sanctioning of the amount needed to conduct the EVLA procedure for poor non-affording patients. Of the 80 patients with varicose veins who presented to our institute, 95% patients had a negative family history of varicose veins. In our study, mean duration of disease was  $5.14 \pm 4.67$  years, with a range from 1 to 17 years. Majority of the patients presented had a duration of disease between 1-5 years. None of the patients had disease duration of less than 1 year, suggesting that symptoms of varicose veins need a long time to develop, significant enough for the patient to seek hospital care.

Most of the patients came with one or more of the clinical presentations rather than coming with isolated clinical presentation. Dilated veins, skin changes and edema were the most frequently observed clinical presentations in study patients. Bradbury A et al[13] have observed that most common clinical presentation of the varicose vein patient was edema of the limb. We have not considered cumulative assessment of all the symptoms of the patient but importance has been given to the chief complaint with which the patient presented to the hospital. In our study, 35% of patients had bilateral affection, 35% patients had left sided affection and 30% patients had right sided affection. Shepherd AC et al[17] have observed bilateral varicose veins in 53% of the patients, whereas Mukunda et al have observed that 47.62% of patients had left lower limb varicose veins, 42.86% patients had right sided varicose veins, and only 9.52% of the patients had bilateral varicose veins.

More incompetence was seen on the left side saphenofemoral junction. The probable reason for this could be the relatively long length of the left common iliac vein, adding a significant pressure to the left sided SFJ. According to CEAP classification, majority of the patients were in Grade C6, followed by Grade C4. Majority of the patient studied by Mukunda et al were C3 followed by C6. This shows that the prevalence and true incidence of complications associated with varicose veins is very high. The mean energy required for treatment of left GSV was  $3219.88 \pm 604.24$  J and for right GSV was  $4072.65 \pm 997.26$  J and the mean energy required for treatment of left SSV was  $1010.60 \pm 64.71$  J and for right SSV was  $1054.83 \pm 103.99$  J, respectively. In the study done by Vourliotakis G et al[20], the average energy used for EVLA of GSV was  $3986.6 \pm 934.9$  J and for SSV was  $1643.5 \pm 534.1$  J. The difference in energy required for SSV ablation might be on account of the lower average diameter of the SSV as compared to the study done by Vourliotakis G et al[20].

Nerve injury and anesthetic complications were the most common complications seen in our study. In the study done by Mukunda et al, the rate of saphenous nerve injury was 14.2% as against the 27.5% in our study. A Study conducted by Proebstle T et al[21], showed that the rate of early recanalization of the GSV post EVLA was less than 10% which needed further treatment by either repeat EVLA or open surgery. Our study showed only 1 case of partial recanalization of the GSV which needed repeat EVLA. Recanalization was predicted to be due to the instrumental failure (no laser energy delivered).

### **Conclusion**

EVLA is a safe and reliable minimally invasive procedure to treat varicose vein diseases and its complications. There are minimal post-operative complications. The complications are not life threatening and can be dealt with conservatively. A high success rate of 98.7% is noted by our technique of EVLA.

### **References:**

1. Vuylsteke, Marc. (2012). Endovenous laser ablation. 10.13140/RG.2.1.3770.9849.
2. Disselhoff, Ben & Rem, Alex & Verdaasdonk, Rudolf & Kinderen, D & Moll, Frans. (2008). Endovenous laser ablation: An experimental study on the mechanism of action. *Phlebology / Venous Forum of the Royal Society of Medicine*. 23. 69-76. 10.1258/phleb.2007.007038.
3. K. Rajgopal shenoy, Varicose veins and deep vein thrombosis, “Manipal manual of Surgery”, Millenium edition, 2019
4. Müller L, Alm J (2020) Feasibility and technique of endovenous laser ablation (EVLA) of recurrent varicose veins deriving from the sapheno-femoral junction—A case series of 35 consecutive procedures. *PLoS ONE* 15(7): e0235656.
5. Wesley Moore MD. Varicose veins, post phlebitis Syndrome and Chronic venous efficiency, “Vascular surgery A comprehensive review,” 2<sup>nd</sup> Edition, pg 1093-1117.
6. Corol E. H. Scott-Conner, David L. Dawson. Ligation, stripping and Harvesting of the Saphenous vein, “Operative Anatomy,” 2<sup>nd</sup> edition, pg 655-662.
7. R. K. Mackenzie et al. “The effect of long saphenous vein stripping on quality of life,” *J Vasc surg* 2002; 35: 1197-1203.
8. Nisar A et al. “Local Anaesthetic Flush Reduces post-operative pain and hematoma formation after, Great saphenous vein stripping: A randomized control trial.” *Eur J Vasc endovasc surg*. 2005 Oct 14 (E pub ahead of print) Entrez pub med Htm

9. S. M. Elias and K. L. Fraiser. “Minimally invasive vein surgery : The role in the treatment of venous stasis ulceration”, AJS 188 (suppl of July 2004) 26s-30s.
10. John H. Scurr and Philip D. Coleridge Smith. “Bailey and Love’s Short practice of surgery”, 27<sup>th</sup> Edition, Edited by R.C.G. Russell, Norman S. Williams, and Christopher j. K. Bulstrode
11. M Wayne Flye M.D. Venous disorders, ‘Sabiston textbook of surgery,’ 14<sup>th</sup> edition, pg 1490-1512.
12. Petor L. Williams. “Gray’s Anatomy”, 37<sup>th</sup> edition, ELBS with Churchill Living stone, 1993, pg 812-814.
13. Bradbury A, Evans C, Allan P, Lee A, Ruckley CV, Fowkes FGR. What are the symptoms of varicose veins? Edinburgh Vein Study cross-sectional population survey. BMJ 1999;318:353-6.
14. Malhotra S. L. “An epidemiological study of varicose veins in Indian railroad workers from the South and North of India, with special reference to the causation and prevention of varicose veins”, Int. J. Epidemiol, 1972, 1: 177-83.
15. Wright et al. “The prevalence of venous disease in a west London population. In: Davy A, stemmer R, Eds. Phlebology’ 89. Paris: John libbey Eurotext, 1989: 176-8.
16. Burkitt et al. “Varicose veins in India,” Lancet 1975; ii: 765-769.
17. A. C. Shepherd, M. S. Gohel, L. C. Brown, M. J. Metcalfe, M. Hamish and A. H. Davies. Randomized clinical trial of VNUS ClosureFAST™ radiofrequency ablation versus laser for varicose veins Imperial Vascular Unit, Department of Surgery, Division of Surgery and Cancer, Imperial College, Charing Cross Hospital, London, UK
18. Mekky et al. “Varicose veins in women cotton workers: An epidemiological study in England and Egypt”. BMJ 1969; ii: 591-5.
19. Leipnitz et al. “Prevalence of venous disease in the population: first results from a prospective study carried out in greater Aachen”, In: Davy A, Stemmer R, Eds, Phlebology’ 89. Paris: John libbey Eurotext, 1989: 169-71.
20. Vourliotakis G, Sahsamans G, Evagelidis P, Aivatidi C. Endovascular laser treatment of incompetent saphenous veins using the 1470 nm diode laser and radial fiber. Ann Med Surg (Lond). 2017;25:12-16. Published 2017 Dec 7.  
doi:10.1016/j.amsu.2017.12.002

21. Proebstle, T & Gül, D & Lehr, HA & Kargl, A & Knop, J. (2003). Infrequent early recanalization of greater saphenous vein after endovenous LASER treatment. Journal of vascular surgery: official publication, the Society for Vascular Surgery [and] International Society for Cardiovascular Surgery, North American Chapter. 38. 511-6. 10.1016/S0741-5214(03)00420-8.